

Unusual arterial injury following a fracture of the forearm bones: A case report

VS Pai

Hastings Memorial Hospital, Hastings, New Zealand.

ABSTRACT

The author describes a case of a 10-year-old boy with fracture of both forearm bones and a concomitant partial rupture of the ulnar artery. The damage to the ulnar artery was repaired at the time of fasciotomy with a good functional outcome.

Key words: *ulnar artery tear, forearm fracture, compartment syndrome*

INTRODUCTION

Injury of an artery, following closed injury from fracture of proximal long bones and dislocations of elbow and knee, has been well described in the literature.⁴ Traumatic rupture of the ulnar artery following a closed fracture of both forearm bones is rare. The author describes a patient who sustained a forearm fracture with a partially severed ulnar artery leading to compartment syndrome.

CASE REPORT

A 10-year-old boy fell onto his outstretched left hand while skateboarding. Clinical and radiographic

examination in the accident department revealed a fracture of both bones of his forearm with minimal displacement and the overall position was acceptable (Fig. 1). However, clinical examination showed a tense swelling in the proximal third of the forearm with a bluish discoloration about 4 cm by 4 cm over the anteromedial aspect of the forearm (Fig. 2). Distal pulses and capillary return appeared to be adequate. There was no evidence of loss of sensation in the distribution of the median nerve.

In view of this tense swelling, he was admitted for observation for compartment syndrome. His symptoms deteriorated in the next 4 hours with the appearance of a tingly feeling in the fingers and stretch pain. On the same day, the forearm muscles were decompressed through an anterior incision. About 50 ml of clotted blood was removed. Bleeding appeared to be from a partially severed ulnar artery (Fig. 3). This was repaired with 6/0 nylon. The fracture radius was stabilized with a DCP plate and the fractured ulna appeared to be stable and well aligned so it was left without any fixation. There was no evidence of muscle necrosis. Postoperatively, a well padded black slab was applied. He was discharged 2 days after admission as he was totally asymptomatic and his finger movements and sensation were normal. The cast was removed at 6 weeks. At follow-up after 24 months he had normal motion of the elbow and excellent hand function with intact neurology. There were no symptoms of claudication, weakness, or cold sensitivity.

Address correspondence and reprint requests to: Dr VS Pai, Hastings Memorial Hospital, Hastings, New Zealand.

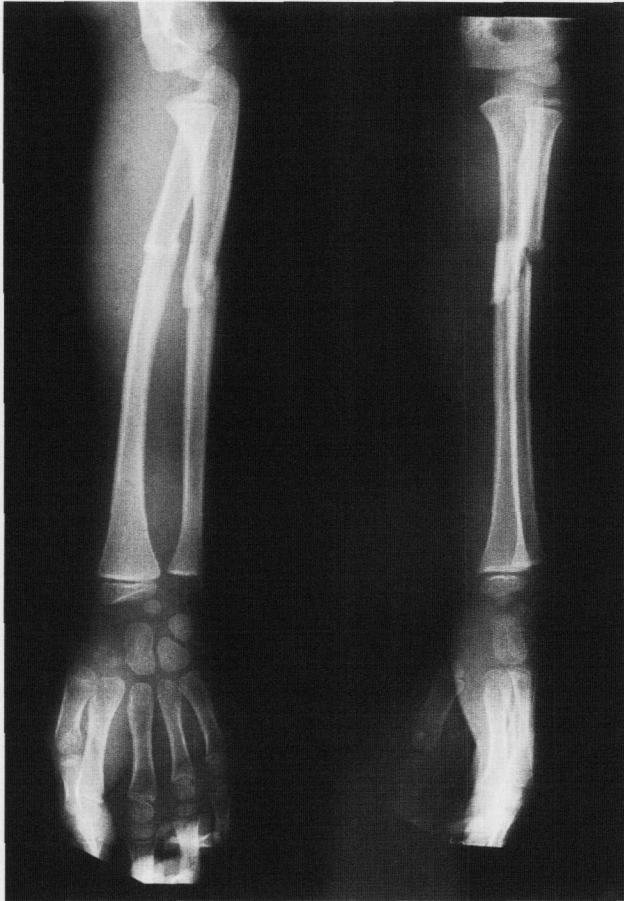


Figure 1 X-ray showing a closed fracture of both forearm bones with a significant soft tissue swelling.

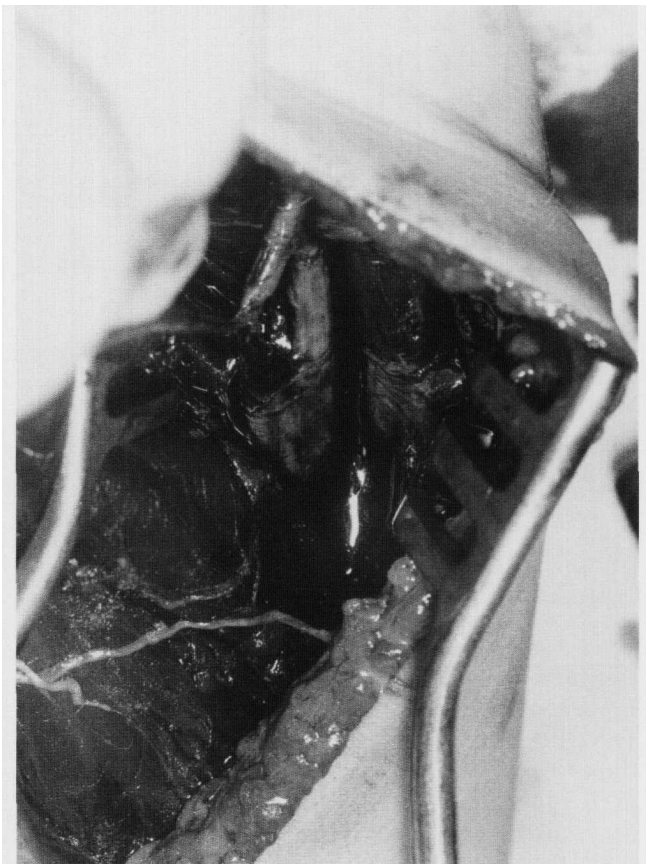


Figure 3 Intra-operative photograph showing the partially severed ulnar artery in the middle third of the forearm.

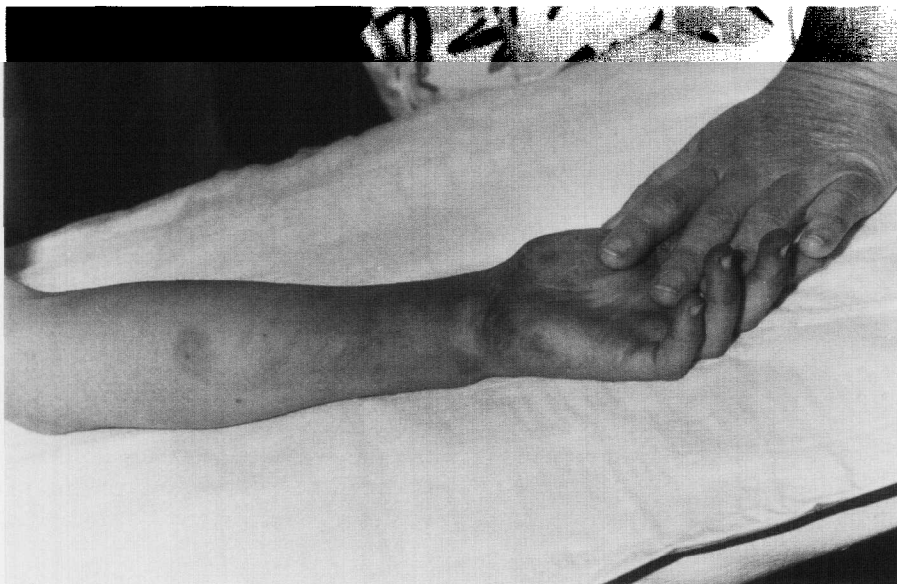

Figure 2 A tense swelling in the proximal third of the forearm with a bluish discoloration in the region of the fracture.

DISCUSSION

Damage to the ulnar or radial artery in the forearm has been reported following laceration,^{1,4,8} gunshot wounds⁶ and open fractures.^{2,5} However, vascular complications of closed fractures of the forearm are rare in contrast to elbow injury.⁷ The diagnosis of an isolated injury of the ulnar artery may not be easy as the injury may not result in typical symptoms of acute ischaemia.¹ When the diagnosis is missed it may present as a traumatic aneurysm of the ulnar artery³ or a compartment syndrome.⁸

Damage to the ulnar artery in the forearm is very rare as it is separated from the ulna in the proximal two-thirds by the bulk of the flexor digitorum profundus muscle. In the present case the author suspects direct puncture by a bony prominence as the cause for partial rupture of the artery. It is possible to speculate that when arteries are divided partially as in this case more bleeding may occur than if the artery is completely severed. Haematoma in the tight flexor compartment may cause impending or well

established compartment syndrome.⁸ In this case, the presence of a tense localised swelling with discolouration of the overlying skin at the site of fracture, as well as worsening of stretch pain, led us to diagnose the severity of the injury promptly.

The management of isolated arterial injury in the forearm has been well described.^{1,2,4} These series suggest that in the absence of acute hand ischaemia, simple ligation of a lacerated radial or ulnar artery is safe and cost-effective. As the reconstruction of a partially severed artery presents a minimal challenge, the author repaired the artery in the reported case.

ACKNOWLEDGEMENTS

The author is grateful to Dr Peter Lloyd for his help in preparing this manuscript and to Mr Wayne Blair, medical photographer, Memorial Hospital.

No benefits in any form have been received or will be received from any commercial party related directly or indirectly to the subject of this article.

REFERENCES

1. **Aftabuddin M, Islam N, Jafar AHM, Haque E, Alimuzzaman M.** Management of isolated radial or ulnar arteries at the forearm. *J Trauma* 1995, 38:149.
2. **Ballard JL, Bunt TJ, Malone JM.** Management of small artery vascular trauma. *American J Surg* 1992, 164(4):316.
3. **Cron J, Saliou C, Fabiani J.** Traumatic aneurysm of the ulnar artery in a child. *Injury* 1997, 28:401.
4. **Johnson M, Ford M, Johansen K.** Radial or ulnar artery laceration: Repair or ligate? *Arch Surg* 1993, 128(9):974.
5. **Katsamouris AN, Steriopoulos K, Katonis P, Christou K, Drositis J, Lefaki T, Vassilakis S, Dretakis E.** Limb arterial injuries associated with limb fractures: Clinical presentation, assessment and management. *Eur J Vasc Endovasc Surg* 1995, 9(1):64.
6. **Lenihan MR, Brien WW, Gellman H, Itamura J, Kuschner SH.** Fractures of the forearm resulting from low-velocity gunshot wounds. *J Orthop Trauma* 1992, 6(1):32.
7. **Louis DS, Ricciardi JE, Spengler DM.** Arterial injury: A complication of posterior elbow dislocations: A clinical and anatomical study. *J Bone Joint Surg [A]* 1974, 56-A:1331.
8. **Pai VS.** Unrecognised arterial injury of the forearm: Presenting as acute compartment syndrome. *NZ Med J* 1995, 108:368.