

Repair of spondylolytic defect with a cable screw reconstruction

Vasudeva S. Pai · Bruce Hodgson · Vishal Pai

Received: 7 September 2006 / Accepted: 8 September 2006 / Published online: 13 April 2007
© Springer-Verlag 2007

Abstract We present the clinical and radiological results of surgical repair for refractory spondylolysis in 20 patients at a minimum follow-up of 2 years. Seventeen of them were reassessed after 5 years. The Oswestry scores revealed good to excellent results in 90% (18/20 patients), indicating a good outcome with surgical repair using two techniques: the Scott procedure or pedicle screw and wire technique. Radiological pseudarthrosis was 10%, which was quite consistent with reported series. CT scanning of the 14 patients after a mean of 13 months revealed complete healing of the fracture in 7 patients, partial in 2 and frank non-union in 5. Overall, CT examination with reversed gantry showed only 7/14 (50%) healing, indicating that radiological healing on plain X-ray is not always suggestive of complete bony healing. However, CT healing is not a sine qua non of good to excellent clinical outcome.

Résumé Nous présentons les résultats cliniques et radiologiques des 20 patients présentant une récurrence de spondylolyse avec un minimum de recul de 5 ans (7.5 ans). Le score d'Oswestry a montré un bon et un excellent résultat chez 90% des patients (18/20) en utilisant deux techniques, la

technique de Scott ou la technique des vis pédiculaires avec fil métallique. La pseudarthrose radiologique est de 10%. Un scanner réalisé chez 14 patients avec un recul de 13 mois a montré une guérison complète de la fracture chez 7 patients, partielle chez 2 et une pseudarthrose dans 5 cas. L'examen au scanner a mis en évidence que le taux de guérison radiologique n'était que de 50%, néanmoins cette consolidation scannographique n'est pas nécessaire pour avoir un bon résultat final sur le plan clinique.

Introduction

Lumbar spondylolytic defect is seen in 6% of the general population and is usually asymptomatic.

When symptomatic, it is usually associated with weight lifters, football players, gymnasts, wrestlers, tennis players, cricket players and other sport participants [14].

Repair of the spondylolytic (pars interarticularis) defect is an appealing option for symptomatic patients who have failed to respond to conservative treatment. Several techniques have been described [1, 11, 12, 16–19], and the success rate has been reported between 80% to 100% [2].

Dreyzin [3] concluded from a biomechanical analysis that repair using a screw had the greatest strength. The use of Songer cable around the spinous process in addition to pedicle fixation further increased the strength of fixation [3, 19].

For the past 10 years, the senior author (B.H.) has performed direct repair of the spondylolysis or grade 1 listhesis with a Scott procedure or a pedicle screw-cable system. Our aim is to assess the clinical and radiological results of this treatment in 20 patients. All patients were followed up in 2000 and 2004 to see whether there was any deterioration.

V. S. Pai (✉)
Department of Orthopedics, Healthcare Hawkes Bay,
Omahu Road,
Hastings, New Zealand
e-mail: vasu_chitra@slingshot.co.nz

B. Hodgson
Dunedin Hospital,
Dunedin, New Zealand

V. Pai
Wellington Medical School,
Wellington, New Zealand

Table 1 Patient details

Patient	Age/sex	Job	Site	Type of defect	Limitation	Results	Follow-up (years)	Results 2000	Results 2004
1	17/F	Sport	*L5	Bil lytic	Sports/sleep	Scott's	7	Exc	Exc
2	22/M	Builder	L5	Bil lytic	Sports/walk/work	Scott's	6	Fair	LFU
3	16/M	Student	L5	Mixed	Sports/work	Scott's	7	Exc	Exc
4	21/F	Sport	L3	Mixed	Sports/sleep	PS	8	Exc	Exc
5	34/M	Horse trainer	*L5	Bil lytic	Walk/sleep/work	PS	9	Exc	Good
6	15/M	Student	L5	Bil lytic	Sports	PS	9	Exc	Exc
7	25/M	Projectionist	L3:L5	Bil lytic	Work/walk/sports	PS L5=Graft	5	Exc	Exc
8	16/M	Student	L4:L5	Bil lytic	Sports/lifting	Scott's	7	Exc	LFU
9	22/M	Tap maker	L5	Bil lytic	Sports/sleep/work	PS	6	Exc	Exc
10	17/F	Student	L5	Mixed	Sports/walk	PS	7	Exc	Exc
11	18/M	Student	L3	Bil lytic	Sports/lifting	Scott's	10	Good	Exc
12	32/M	Dye setter	L5	Bil lytic	Sports/ work	PS	11	Good	Exc
13	56/F	Cleaner	L4:*L5	Bil lytic	Work	L4 PS L5-1 Fus	8	Poor	Fair
14	16/M	Baker's assistant	L5	Bil lytic	Sports/work	PS	7	Exc	LFU
15	36/M	Builder	L5	Bil lytic	Work/sports/run	PS	9	Exc	Exc
16	16/F	Student	L5	Mixed	Sports	PS	7	Exc	Good
17	17/M	Student	L4	Mixed	Sports/ gym	PS	6	Exc	Good
18	23/M	Carpenter	L5	Bil lytic	Work/sports/lift	PS	10	Good	Good
19	22/M	Teacher	L5	Bil lytic	Sports	PS+disc	6	Exc	Exc
20	17/M	Student	L5	Bil lytic	Sports/work/lift	PS	5	Exc	Exc

*L, listhesis; mixed, lytic/sclerosis; PS, pedicle screw+tension band wire (van Dam procedure); Scott's, Scott's procedure; LFU, lost to follow-up

Patients and methods

Between 1994 and 2000, the senior surgeon (B.H.) operated on 20 consecutive patients for spondylolysis or grade I listhesis with pars defect. There were 15 men and 5 women with a mean age of 23 years (16–56) at the time of surgery. Four patients were over 30 years old. There were three national or state level sportsmen, seven students who were

competitive rugby or soccer players, five who were involved in a heavy manual job and five sedentary workers. Demographic data for the patients are listed in Table 1.

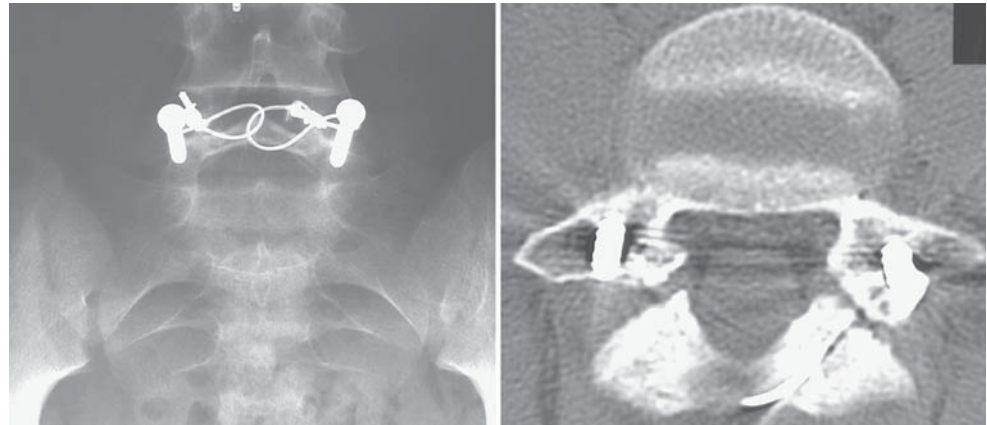
The mean duration of symptoms before surgery was 9 months. All patients had a trial of nonoperative treatment that consisted of one or more of the following: (1) abstinence from sports; (2) brace; (3) education; (4) course of NSAID for a minimum period of 6 months.

Table 2 Preoperative radiological finding (n=20)

Preoperative assessment	
Single or multiple level	
Single	17
Double	3
Type of defect (n=20; sites=23)	
Pure pars defect (spondylolysis)	20
Grade 1 slip	3
Level of lesion	
L5	17
L4	3
L3	3
Type of lesion	
Unilateral lysis	0
Bilateral lysis	18
One side lysis and other side sclerosis	5

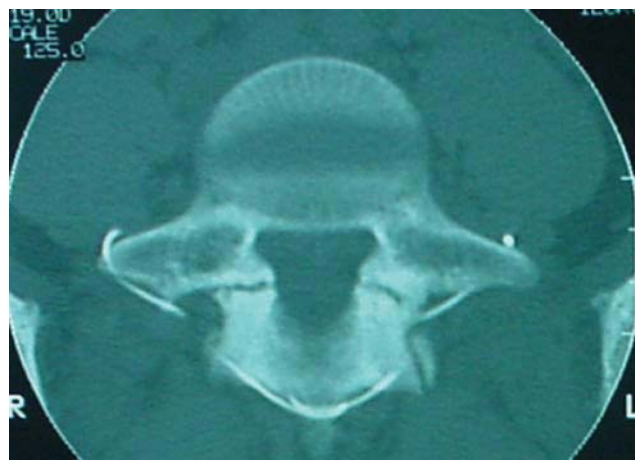**Fig. 1** Scott's procedure

Fig. 2 van Dam procedure



Preoperative assessment included plain radiography (AP, lateral and oblique), with or without bone scan, reverse gantry CT scan and in selected cases MRI and discogram. In three, there was mild (grade I) slip in addition to the pars defect. Contraindications for this procedure were the presence of a listhesis more than 5 mm and significant degenerative changes seen on radiographs or MRI. The common site for the pars defect was L5 pars in 17, L4 in 3 and L3 in 3 patients. All lesions were classified as either unilateral or bilateral, sclerotic or lytic (Table 2).

All patients were treated by the senior surgeon (B.H.) using a Scott procedure [17] or van Dam modification [17] (Figs. 1 and 2), which involved bone grafting of the defect, pedicle screw and a tension band connecting the pedicle screw. In both procedures, a 1-mm double cable (AcroMed Songer cable, Cleveland) was passed around the spinous process and the cable was tensioned to 30 ft/lbs (41 Nm).

Postoperative: mobilisation in a lumbar corset for 3 months, walking and swimming 3 months, range of motion exercises at 3 months. The Oswestry Disability Index [5] was measured in year 2000 and in 2004 (Table 3).

Bony union of the pars was assessed by plain radiographs (AP, lateral and oblique) at 3 and 12 months (Tables 4 and 5). A reverse gantry CT scanning of the involved vertebra was performed on 14 of 20 patients. In six patients, CT was not carried out for various reasons, but mainly due to the fact these patients were back to normal work with excellent results and did not wish to undergo further examinations. Images were examined by a single radiologist who was

blinded with regard to the clinical history and plain radiograph findings. They were interpreted as demonstrating the presence of fusion if there was bridging bone.

Results

The average follow-up was 7.35 years (range: 5–11 years). The Oswestry low back questionnaire used to evaluate results showed the mean ODI (Oswestry Disability Index) was 31. Results in 14 patients were rated as excellent and in 4 as good in the year 2000 and results remained excellent to good in 16 of 17 patients followed up in the year 2004 (Table 3). All but three patients returned to sports or work at their previous levels of activity.

The union of the pars interarticularis as determined with plain oblique, anteroposterior and lateral radiographs of the lumbar spine at 3 months and 12 months showed a bony fusion in 18 of 20 patients (90%).

CT scanning of the 14 patients after a mean of 13 months revealed complete healing of the fracture in 7 patients, partial in 2 and frank non-union in 5. Overall, CT examination with reverse gantry showed only 7/14 (50%) healing, indicating that radiological healing is not always suggestive of complete bony healing (Table 4). This fact was more strongly indicated in the patients in the Van Dam group than in the Scott’s procedure group. It is possible that the presence of pedicle screw may obscure radiological healing on the plain X-ray.

Table 3 Oswestry scores

Oswestry scores	2000 (n=20)	2004 [17]
Excellent (20)	14	12
Good (40)	4	4
Fair (60)	2	1
Poor (80)	0	0

In 2004: three lost to follow-up: working abroad.

Table 4 Radiological and CT healing vs. Oswestry results

	Excellent	Good	Fair	LFU
X-ray union present and CT available	4	2		
X-ray + CT union present	4	2		1
X-ray union present + CT non-union	1	2	1	1
X-ray + CT non-union	1			1

LFU, lost to follow-up

Table 5 Radiological and CT healing vs. surgical technique

Clinical	X-ray (n=20)	CT (n=14)
Healing present	18 (90%)	7 (50%)
Non-union	2 (10%)	7 (50%)
Scott [5]	2/5 (40%)	2/4 (50%)
Van Dam [15]	0/15 (0%)	5/10 (50%)

Despite the high incidence of CT non-union, there is poor correlation between CT non-union and clinical results. Most of the patients with CT non-union had excellent to good clinical results in this series. There were no differences in clinical outcome with regard to sports or job resumption between patients in the different groups of healing as assessed by CT.

There was no correlation of CT non-union to sex, age, occupation or type of defect, i.e., lysis or sclerosis. We could not find any predictors for non-union.

There was one fair result in this study. A 56-year-old cleaner who presented with back pain and left sciatica had disc degeneration at L5-S1 with listhesis of L5 and lysis of L4. She was treated with L5-S1 fusion with tension band fixation of the L4 pars interarticularis. She did badly on Oswestry scoring, and further assessment with CT and MRI showed normal disc above and sound fusion. At present, she is undergoing investigation under a neurologist and psychiatrist.

Discussion

It appears that hypermobility of the loose posterior arch with stimulation of the defective tissue in the pars interarticularis is responsible for pain in spondylolysis. This defective structure is rich in nociceptive nerve endings [7].

The traditional surgical management of symptomatic spondylolysis or minimal isthmic spondylolisthesis is posterolateral fusion as described by Goel [8] or Gill's decompression of the loose lamina [6] with or without fusion. Buck [1] described a technique of direct repair of the pars defect by placing a screw across the defect in addition to cancellous bone graft. This was further improved by Morscher [12] with the use of a hook screw in 1984. However, these techniques are difficult, and the screw interferes with the potential area for bone incorporation.

There are some studies in the literature on the indirect surgical techniques available for spondylolysis. Scott [17] described a tension band fixation by placing 18-gauge SS wire around the transverse process and then tightening these wires to the posterior spinous process. This technique needs extensive exposure, and fixation is dependent on the transverse process, which is not very strong. This technique was further simplified by Salib [16] and Songer [18] using a pedicle screw and wire or cable system to achieve strong fixation. Van Dam [19] further modified Songer's technique by passing a cable around the spinous process instead of the sublaminar position.

Our modification passes the cable around the spinous process instead of the sublaminar fixation. Repair of spondylolysis has the advantage of retaining segmental movement, and it is hoped this will avoid any stress transfer to adjacent mobile vertebral segments. However, this procedure is not advocated when there is disc degeneration in the mobile segment. We, in selected cases over 25 years, performed MRI to check the disc status.

As there is increased incidence of disc degeneration in the general population above the age of 30 years, it is wiser to select younger patients for surgery [4]. Hefti [9] reported a successful outcome of 88% in patients less than 20 and 71% in patients over 20 years. The primary reason for failure of fixation in the older population is due to the

Table 6 Comparative published results used to repair spondylolysis

Authors	Direct repair technique	Patients (n)	Results(%)
Buck	Laminar AO screws	75	88
Pederson and Hagen	Laminar AO screws	18	83
Roca	Laminar AO screws	15	87
Debanath	Figure of eight	3	
	Laminar AO screw	18	82%
Scott	Figure-of-eight wiring	7	85
Bradford and Iza	Figure-of-eight wiring	22	90
Morscher	Hook screws	12	83
Albassir	Hook screws	37	78
Hefti	Hook screws	33	88 (20 years) 71 > 20 years
Kakiuchi	Pedicle screws and laminar hook	16	81.5
Gillet and Petit	V rod and pedicle screws	10	90
Pai and Hodgson	Pedicle screw and wire	15	95%
	Figure-of-eight wiring	5	100%

presence of degenerative disc disease [18]. Buck [1] originally suggested that his technique was appropriate only in patients in whom there was lysis of less than 3 mm. As the size of the defect increases, there is gradual progression of the slip in some patients with an increased risk of disc degeneration [2].

In this series, the repair of lumbar spondylolysis by a cable and pedicle system in active young adults resulted in a significant improvement in the Oswestry scores in all but one patient. The result reported by various techniques of surgical repair has been compared with our technique in Table 6. The literature is not clear about the objective assessment of outcome. Plain static radiographs are widely used in the assessment of fusion status, mainly because of their low cost and easy availability [1, 2, 10, 12].

However, there are major concerns regarding this assessment and the reliability of the reported fusion rates. Our findings showed a much higher fusion rate (90%) from assessment using plain static radiographs than from evaluation with a reverse gantry CT (50%). We believe that these findings reflect the inability of static plain radiographs to detect non-unions, leading to an overestimated incidence of fusion. The flaw with plain radiographs seems to lie in the fact they provide projected images in two planes and therefore cannot accurately detect fusion, which is three-dimensional [15].

Using radiological criteria, the pseudarthrosis rate in our study was 10%, which is consistent with the previously reported large series [2, 10, 12, 13]. However, incidence of non-union was as high as 50% when CT examination was used. It has to be noted that the CT non-union did not appear to affect clinical results, indicating that bony fusion is not required to achieve good results. It is possible that the symptoms in spondylolysis improved after surgery due to the absence of movement at the pars interarticularis from fixation. The exact cause for non-healing on CT after rigid fixation with a cable and pedicle system is not known.

Irrespective of CT findings, the clinical outcome following this modified Scott's procedure or Van Dam procedure is excellent. This modification is simple, effective and biomechanically sound, and a functional segment can be saved. The advantage of direct pars repair over segmental instrumentation is the preservation of the anatomical integrity and motion of the affected segment.

References

1. Buck JE (1970) Further thoughts on direct repair of the defect in spondylolysis. *J Bone Joint Surg [Br]* 61:123
2. Debnath UK, Freeman BJC, Gregory P, de la Harpe D, Kerslake RW, Webb JK (2003) Clinical outcome and return to sport after the surgical treatment of spondylolysis in young athletes. *Bone Joint Surg Br* 85(2):244
3. Dreyzin V, Esses SI (1994) A comparative analysis of spondylolysis repair. *Spine* 19(17):1909, 1
4. Elliot BC, Davis JW, Khangure MS, Hardcastle PH, Foster D (1993) Disc degeneration and the young fast bowler in cricket. *Clin Biomech* 8:227
5. Fairbank J, Couper J, Davies J, O'Brien J (1980) The Oswestry low back questionnaire. *Physiotherapy* 66:271
6. Gill GG, Manning JG, White HL (1955) Surgical treatment of spondylolisthesis without spine fusion. *J Bone Joint Surg [Br]* 37:493
7. Gillet P, Petit M (1999) Direct repair of spondylolysis without spondylolisthesis, using a rod-screw construct and bone grafting of the pars defect. *Spine* 24(12):1252
8. Goel VK, Lim TH (1989) Mechanics of spondylolisthesis. *Semin Spine Surg* 1:95
9. Hefti F (1997) Direct screw repair spondylolysis with the hooked screw. *Orthopade* 26:769
10. Ivancic GM, Pink TP, Achatz W, Ward JC, Homann NC, May M (2003) Direct stabilization of lumbar spondylolysis with a hook screw: mean 11-year follow-up period for 113 patients. *Spine* 28(3):255
11. Kakiuchi M (1997) Repair of the defect in spondylolysis: durable fixation with pedicle screw and laminar hooks. *J Bone Joint Surg [Am]* 79-A:818
12. Morscher E, Gerber B, Fasel J (1984) Surgical treatment of spondylolisthesis by bone grafting and direct stabilization of spondylolysis by means of a hook screw. *Arch Orthop Trauma Surg* 103:175
13. Pedersen AK, Hagen R (1988) Spondylolysis and spondylolisthesis—treatment by internal fixation and bone grafting of the defect. *J Bone Joint Surg [Am]* 70:15
14. Rossi F, Dragoni S (1990) Lumbar spondylolysis: occurrence in competitive athletes: updated achievements in a series of 390 cases. *J Sports Med Phys Fitness* 30:450
15. Santos ER, Goss DG, Morcom RK, Fraser RD (2003) Radiologic assessment of interbody fusion using carbon fiber cages. *Spine* 28(10):997
16. Salib RM, Pettine KA (1993) Modified repair of a defect in spondylolysis or mild spondylolisthesis by pedicle screw, segmental wire fixation, and bone grafting. *Spine* 18(4):440, 15
17. Scott JHS (1987) The Edinburgh repair of isthmic spondylolysis. *J Bone Joint Surg [Br]* 69:491
18. Songer MN, Rovin R (1998) Repair of the pars interarticularis defect with a cable screw construct: a preliminary report. *Spine* 23:263
19. van Dam BE (1997) Modified Scott technique. In: Bridwell KH, DeWald RL (eds). *Textbook of spinal surgery*, 2nd edn. Lippincott, Philadelphia