

CARPAL TUNNEL SYNDROME

History

Paget (1854)	Recognized this problem
Marie & Foix	Described the pathology of nerve entrapment
Phalen	Popularised this diagnosis

Pathoanatomy

The median nerve [C5,C6,C7,C8,T1] travels lateral to the brachial artery. It then crosses to the medial side at the mid arm. No branches occur in the upper arm. It runs between the 2 heads of the pronator teres at the elbow.

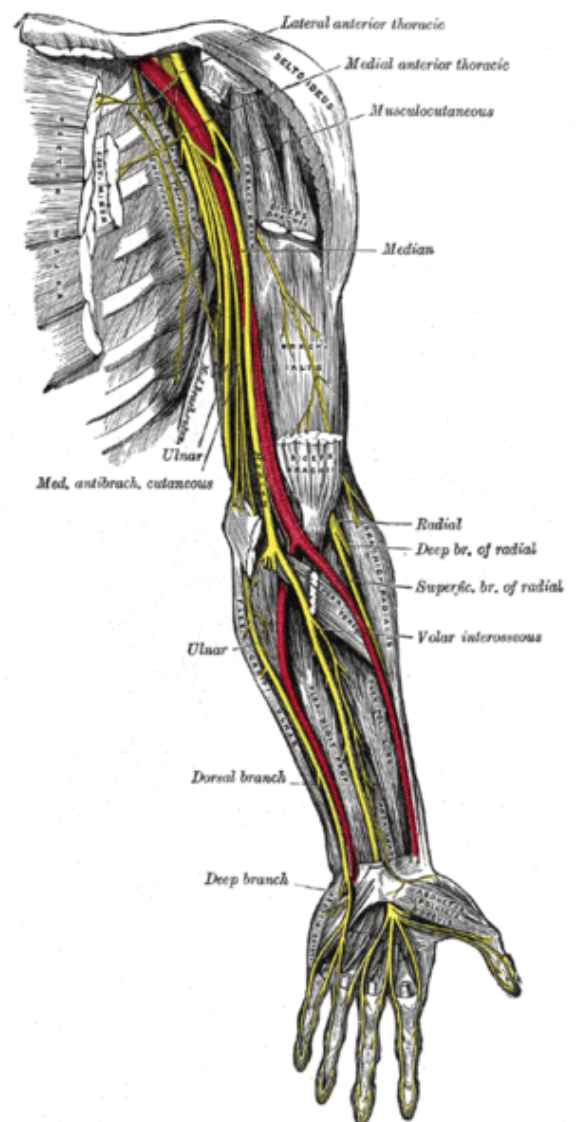
5-6cm distal to elbow, the anterior interosseous branch arises. It gives motor branches FPL, FDP of Index and middle finger, pronator quadratus.

The superficial flexors are supplied by the median nerve

The palmar cutaneous branch, arising 5cm proximal to the wrist, runs between the FCR and the palmaris longus and is superficial to the flexor retinaculum.

The median nerve then runs through the carpal tunnel and a recurrent motor branch to the thenar muscles arises at the distal end of the carpal tunnel.

It terminates in sensory branches to supply the radial 3 1/2 digits



Pathogenesis

The exact cause for CTS is unknown. It has been demonstrated by CT, that there is a decrease in the cross sectional area of the carpal tunnel.

The anomalous anatomical causes are

1. An over large lumbrical, or other, anomalous muscle.
2. Distal extension of FDS and or FDP.

.

Intracarpal canal pressures [Gelberman]

Pressure is significantly elevated in patients with CTS compared to control subjects.

	Normal	CTS [mm Hg]
Wrist in neutral	2.5	30
90° Flexion	30	90
90 ° Extension	30	90

Pathology

Repetitive use: tenosynovitis is present in only 10% of cases?.

No evidence of inflammation in idiopathic CTS

CTS tissue: 5 fold increase in IL1, IL6 and PGE2

Causes

Idiopathic

Colles, Cushings, Carpal dislocation

Rheumatoid Tenosynovitis of the wrist

Acromegaly, amyloid

Myxoedeoma, mass, (diabetes) mellitus

Pregnancy

Sarcoidosis, SLE

Clinical Features

Height: taller people are less at risk

Ethnicity: CPS 5 times more common in white races [?Genetic]

Gender: 3 times more females affected than males.

Handedness: dominant hand frequently affected.

Alcohol and tobacco: increased incidence of CTS in users.

Bilaterality: 87%, one side may be asymptomatic and detectable only by EMG

Symptoms and Signs

Aching and parasthesia in thumb, index middle and half of ring finger; more intense at night

Clumsiness, dropping things

In severe cases, thenar wasting and trophic ulcers may develop check

Weakness of thumb abduction

No single test is fully reliable

Tinel's sign: 74% sensitivity, 91% specificity. A tap between PL and FCR at the wrist crease produces paraesthesia in the distribution of the median nerve.

Phalen's manoeuvre : 61% sensitivity, 83% specificity . With elbows on the table, allow the wrists to flex passively. Any manifestation of symptoms within 60 minutes is suggestive of CTS

Median nerve compression test – 86% sensitivity, 95% specificity. With elbow extended, forearm in supination, wrist flexed to 60 degrees digital pressure is applied with one thumb over the carpal tunnel. Test is positive if parasthesia or numbness occurs within 30 sec.

Hand diagram [Patient's perception]

Symptoms usually felt in radial finger but not in the palm

Direct hydrostatic pressure [Wick catheter]

>25mm of Hg. Not very reliable

Static two point to light touch

>6mm apart

Semmes Weinstein

>2.83 cm [83% sensitive]

Nerve conduction studies [NCS]

Distal sensory latency >3.5 mm/sec

Or asymmetry greater than 0.5 mm

Distal motor latency >4.5 mm/se

Or asymmetry greater than 1 mm

EMG: Very advanced. Denervation of thenar muscles.

A positive NCS with clinical symptoms and signs confirms the diagnosis of carpal tunnel syndrome

Differential diagnoses

Cervical radiculopathy

Spinal cord lesions - tumour, MS, syrinx

Peripheral neuropathy of toxic, alcoholic, uraemic or diabetic origin

Proximal median nerve entrapment

Treatment

Conservative-

Non-steroidal anti-inflammatory

Activity modification

Futura splint

Kenacort, injection (80% relief steroid: lasts for 12 months in only 20%)

Surgical-

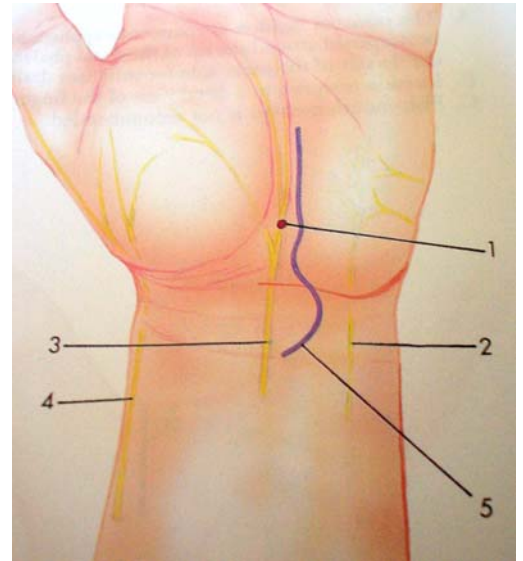
Open/endoscopic decompression.

Open is preferred.

Need to bear in mind anatomical variations

Beware of the palmar cutaneous branch of median nerve,
motor branch

Outcome: 85% successful



Kaplan's cardinal line

From the apex of the thumb index web to the hook of the hamate].

This marks the distal end of the flexor retinaculum.

Incision: 3 mm lateral to the thenar crease and 3 mm proximal to Kaplan's line, remaining ulnar to the palmaris longus at the wrist and crossing the wrist towards the ulnar side.

Divide palmar fascia and some superficial muscular fibres in line with skin incision.

Now divide flexor retinaculum in its full length [not to divide median nerve or thenar branch]

Release proximally antebrachial fascia

Tourniquet release and haemostasis is achieved

Skin is repaired with interrupted nylon after tourniquet release.

Bulky dressing

Endoscopic: Chow 2 portal technique. Only to be undertaken by experts as there is increased risk of nerve damage and incomplete division of the retinaculum.

After surgery

Pillar Pain: Aching pain in the thenar and hypothenar regions, either side of the wound may take 3 months to settle.

Grip strength: 50% at 6 weeks and maximum at 6 months

In 15% of cases, grip strength may never return to normal.

Complications

Arise in 10% of cases

1. Complex regional pain syndrome
2. Pillar pain
3. Neuroma in palmar cutaneous branch of median nerve
4. Division of recurrent branch of median nerve
5. Tenosynovitis / tendon adhesions
6. Bowstringing of tendons

CTS and Pregnancy

Incidence: 10% of more than 2000 pregnant women

Most typically between 28-32 wks of pregnancy

Symptoms persist, post partum, in one third of affected women

One third ultimately require surgery.