

CEREBRAL PALSY

Epidemiology

Incidence: 2.5/1000

More common in advanced countries [Advanced perinatal care]

More common in socioeconomically disadvantaged people.

50% have birth weight <2.5 kg

Incidence of athetosis is less these days [is secondary to Rh blood incompatibility]

Definition

Defined as disorder of movement and posturing which is non-progressive secondary to brain damage during intra-uterine, natal and infantile phase.

It's manifestations may change with growth and development

Etiology

Prenatal [30%]	Maternal infection – TORCH T Toxoplasmosis O Other causes: Vericella, Hepatitis B R Rubella C Cytomegalo virus H Herpes Zoster
	Maternal exposure - Alcohol . Drugs
	Congenital brain malformations
Perinatal [60%]	Premature: commonest cause these days. Birth weight <2500g (25-40%) Anoxia (10-20%)
Postnatal [10%]	Meningitis Head injury

Types

Hemiplegic: Mentally normal, walkers and achievers

Quadriplegic have reduced life span; increase scoliosis and dislocation

Athetoid and asteriognosis: do not require surgery

Associated lesions

Seizures	30%
Mental retardation	40% [Normal in Hemiplegic]
Visual impairments	16% [Rare these days]
Hydrocephalus	14%
Complex Movement disorder	20%
Speech delay	
Loss of hearing	Rare since rubella vaccination

Classification

- 1. Spastic:** Hemiplegic, Diplegic, Quadriplegic
Most common (60% of cases)
Most amenable to surgery
UML: Increased muscle tone [Dynamic test]
Hyperreflexia
Slow, restricted movements

2. Hemiplegic

Arm signs were worse than leg [In the leg: Ankle>Knee>Hip]
All hemiplegics will walk, regardless of treatment
Present with toe walking only
Unilateral

3. Diplegia

Lower limb involvement is more than Upper limb
Most diplegics will eventually walk; [75%]
4 gaits: Crouch, Equinus, Apparent Equinus, Jump gait
I.Q. may be normal, strabismus is common
Heel cord lengthening alone may exacerbate crouched gait
Scissoring is mainly due to medial rotation of femur than adduction deformity

4. Paraplegia (both legs): sparing of arms

5. Quadriplegia: Scoliosis is common
Dislocation common
25% walks

6. Athetoid

Slow, Writhing, involuntary movements.
Result from basal ganglia involvement
Affect the extremities (athetoid), or the trunk (dystonic)
Hyperextended hips and knees with exaggerated stepping gait. Lean backwards
Abrupt, jerky distal movements (Choreiform) also may occur
Dysarthria is present and is often severe.

7. Ataxic

10% of cases
Involvement of the cerebellum or its pathways
Weakness, incoordination, and intention tremor produce unsteadiness, wide based gait, and difficulty with rapid or fine movements
Poorly amenable to surgical correction

8. Hemiballistic

Sudden movements as if throw a ball.

9. Hypotonic

Usually a stage through which an infant passes.

Bone Assessment in CP

1. Femoral anteversion [check rotation at the hip]
2. External rotation of tibia: Foot thigh angle
3. Anteversion of femur and external rotation of tibia
Terrible malalignment combination
4. Valgus of the foot: Fixed or not
5. Dislocation or subluxation of the HIP
6. Late: arthritis of the joint

Assessment

History: Abnormal birth history

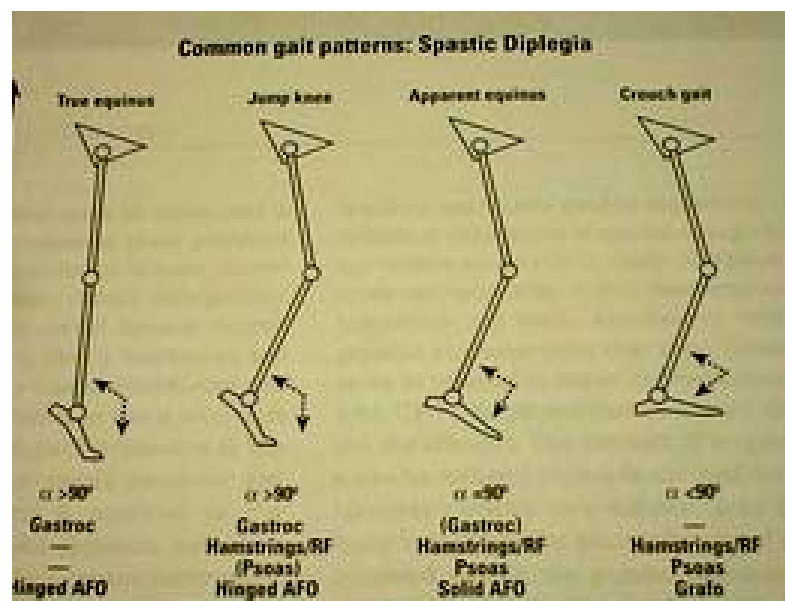
Prematurity

Normal Developmental milestones (brackets are 95th percentile)

Head control	3 months (6 months)
Sitting independently	6 months (9 months)
Pulling to stand	9 months (12 months)
Walking	12 months (18 months)
Ascends chair	2 yrs
Pedals tricycle	3 yrs
Hops on one foot	5 yrs

Clinical

1. Gait: True equinus
Jump gait
Apparent equinus gait
Crouch gait
2. Define deformity



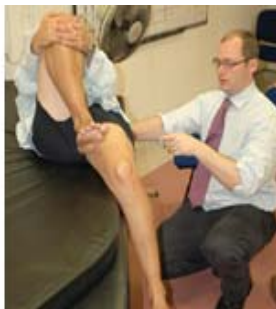- 3. Galeazzi sign
Clinical sign for limb length



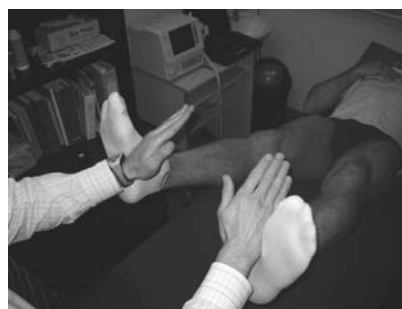- 4. Muscle tightness

- a. Hip flexors Thomas test
- b. Adductors
- c. Iliotibial band contracture Ober's test

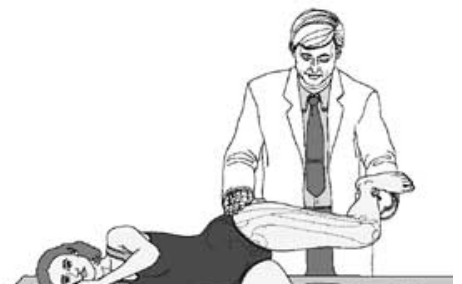1. Thomas Test



2. Adductor Contracture



3. Tight Iliotibial band



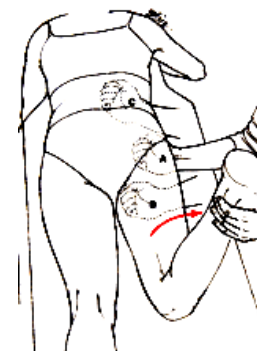- d. Quadriceps contracture

Stiff-legged gait (knees never flex)

Inability to flex knee when hip extended means rectus is responsible

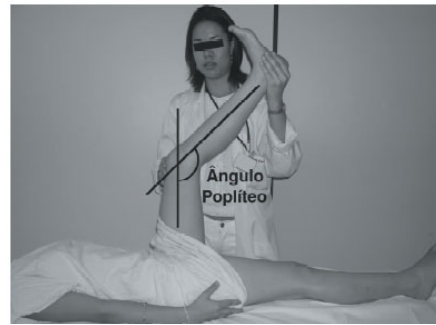Ely test

child in prone,
flex the knee
if hip flexes means
= rectus femoris tight).



e. Hamstring contracture

When between 110-135 is significant Contracture



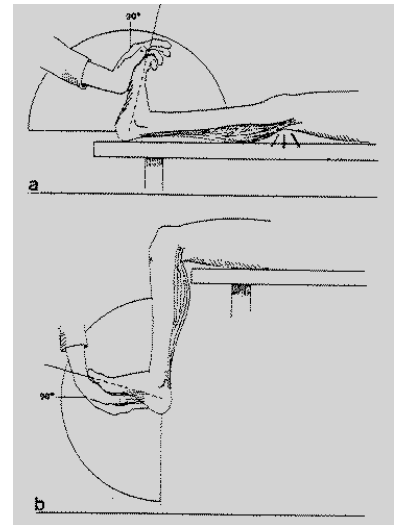
f. Gastrosoleus: Silverskold's Test

Gastro contracture:

dorsiflexion is more ankle with knee in flexion than when knee in extension

Soleus contractue:

dorsiflexion is more ankle with knee in flexion is similar to when knee in extension

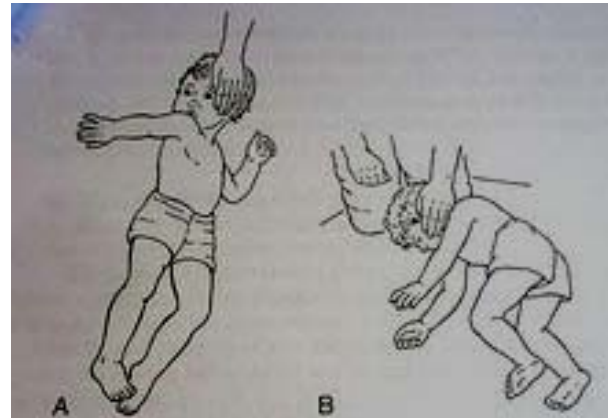


Predictors for walking

a. Asymmetrical tonic neck reflex

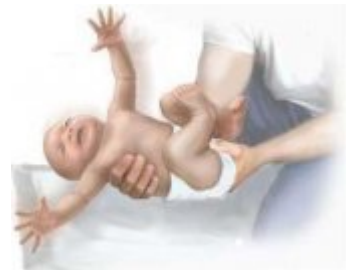When head is turned to the right
Right side extends and left side flexes

[Fencing]

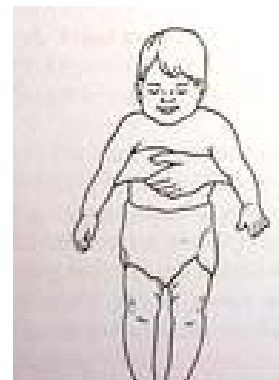

b. **Neck righting reflex:** with passive head turning, the infant can be rolled over and over as rolling log

c. **Moro reflex** Jarring of the table, there is abduction of the arms and followed by the embrace

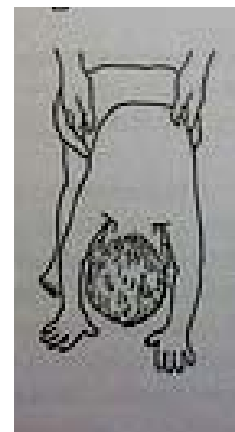


d. **Extensor thrust** When baby held erect by the trunk and lowered to the table top, normally there will be extension of the legs



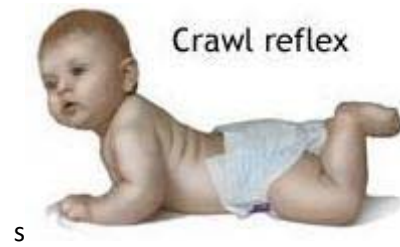e. **Absence of Parachute reflex**

When the baby is held prone and suddenly lowered to the table, the normal response is automatic hand placement



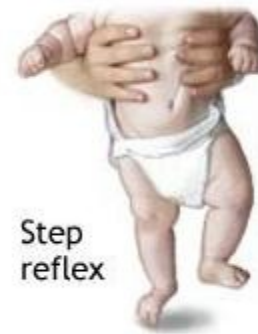f. Symmetrical tonic neck reflex

A normal response in infants to assume the crawl position by extending the arms and bending the knees when the head and neck are extended. The reflex disappears when neurologic and muscular development allows independent limb movement for actual crawling.



g. Absence of stepping reflex

Newborn will step with one foot and then the other in walking motion when one foot is touched to flat surface



If any 2 of these 7 responses are inappropriate by 1 year of age it is highly unlikely that the child will walk independently [Check appendix 1 end of this chapter]

Other Factors

Inability to sit by **2 years**
Head balance: absent at **20 months**

TREATMENT

Multidisciplinary

- | | |
|---------------|---|
| Up to 6 years | Brace/botox and physio stretching |
| > 6 years | Tendon release or lengthening |
| >12 years | Bone surgery is required in addition to soft tissue surgery |

COMMON SURGERIES

HIP

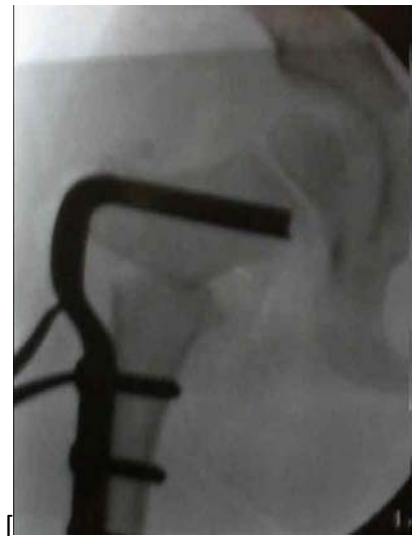1. Adductor Release: Release Adductor longus and Brevis, Gracilis

Obturator nerve neurectomy should never be performed as it causes abduction contracture

2. Psoas elongation: Bikini incision and tendon is released taking care not to damage femoral nerve

3. Varus Femoral rotation osteotomy is indicated when there is Subluxation of the hip.

Proximal or distal femoral Derotation osteotomy is indicated when anteversion is the problem.
Difficult to differentiate a scissoring gait from anteversion or due to medial hamstring.
Gait lab study may be helpful.



KNEE

Treatment for flexion deformity is serial Casting. When this fails, then consider surgery.

The recommended surgeries are:

1. Medial Hamstring lengthening
Release Semitendinosus and gracilis; fractional lengthening of Semimembranosus
2. Transfer Rectus Femoris to Semitendinosus in addition to above
3. Above plus Biceps lengthening and a posterior capsulotomy
4. Distal osteotomy of the femur in some resistant cases

ANKLE

Dynamic casts or orthoses and physiotherapy

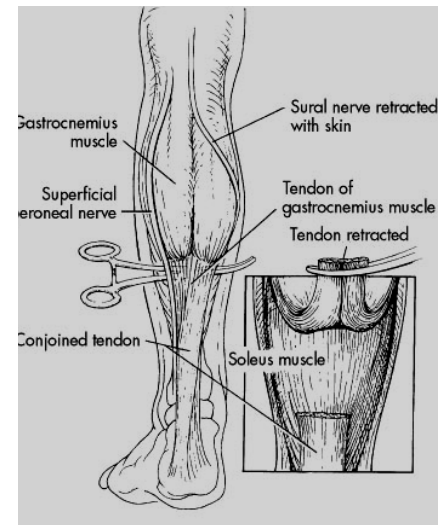
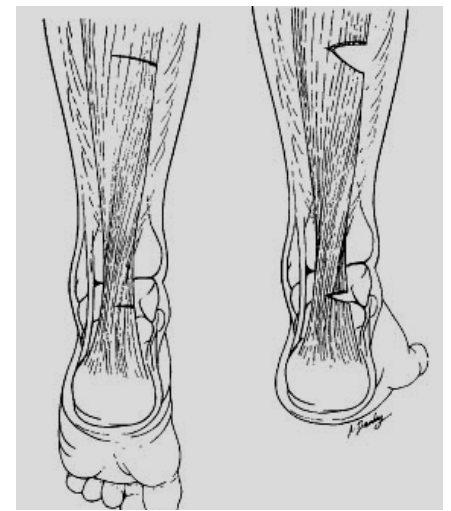
1. IN EQUINUS DEFORMITY

Silverskiold test: Differentiate gastrocnemius contracture from soleus.

White Anterior 1/2 at calcaneum
Medial 1/2 at Musculotendinous junction
Done openly [is more controlled than Percutaneous triple cut of Hoke]

Strayer: Release Gastro aponeurosis from soleus
Stretch gastro by extending the knee and dorsiflexing the foot

Vulpinus: Inverted V release of gastro aponeurosis



EQUINOVALGUS

Is more common in diplegic

Surgical treatment: Subtalar arthrodesis [Dennyson-Fulford : screw and graft]

Grice Green extra-articular arthrodesis

Triple arthrodesis in adults

Dennyson-Fulford_ subtalar arthrodesis of subtalar joint

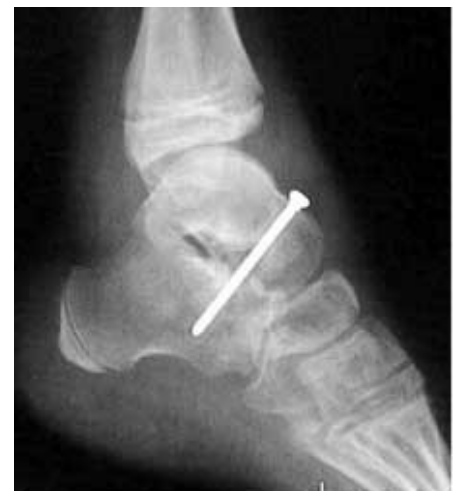Ollier's approach

Short oblique incision from the tip of the fibula to neck of talus

Elevate the Extensor digitorum brevis from its origin from sinus tarsi and reflect it distally

Sinus tarsi fat pad are dissected sharply out of the sinus tarsi.

The calcaneus should be exposed from the posterior facet to its beak



Decortication of the bony surfaces of the space

Screw inserted through the talar neck and into calcaneus [or from calcaneal tuberosity into the neck of the talus

Space packed with bone graft

EQUINOVARUS DEFORMITY

Is more common in Hemiplegic

Varus: common: 1. Tendo Achilles lengthening

2. In addition: Split Tibialis anterior or posterior transfer to Peroneus brevis

3. +/- Supramalleolar osteotomy

4. Triple arthrodesis in adults

RANCH PROCEDURE

Split Tibialis anterior and transfer it to cuboid or peroneus brevis

Gastrocnemius recession

Intramuscular lengthening of tibialis posterior

PLANOVALGUS DEFORMITY

In flexible foot Lateral column lengthening of the foot + Calcaneal lengthening osteotomy

Non flexible foot Grice green or Modified Fulford technique

After 14 years: triple arthrodesis

WRIST

1. Z plasty lengthening of FDS and FDP: in severe tightness
2. Pronator-Flexor slide from the medial epicondyle and Interosseous membrane
3. Release FDP and FDS: for hygiene
4. Green procedure:
 - FCU to ECRB [central tendon]
 - Circumosseous [ulnar border]
 - Do not transfer when FCR is weak
5. Bone surgeries:
 1. I MCP arthrodesis
 2. Wrist arthrodesis
6. I web space contracture
 1. Z plasty skin
 2. Release dorsal interosseous aponeurosis
 3. Release adductor pollicis from the metacarpal
 4. Stabilization of MPJ if there is hyperextension
7. Intrinsic plus finger: Requires release of intrinsic
8. Swan neck: FDS tenodesis

HIP INSTABILITY

Comfortable, upright sitting is a major goal.

Early recognition of instability and prophylactic surgery is essential.

Progressive subluxation to eventual dislocation is seen in 10% in CP.

Subluxation is more common in severe non-ambulant patients.

Hip dislocation in spastic hips is different from DDH

	Spastic ip	DDH
At Birth	Hip is normal	Usually abnormal
Age at risk	>2 yrs	During 1 year
Detection	Serial X rays	Physical and Ultra sound
Etiology	Spastic muscles	Abnormal acetabulum and Ligament laxity
Progression	Progressive subluxation common	Rare
Acetabular deficiency	Supero-lateral	Anterior

Assessment

1. Reimer's migration Percentage and index

Percentage of head uncovered

Migration index: the change in head uncovered over

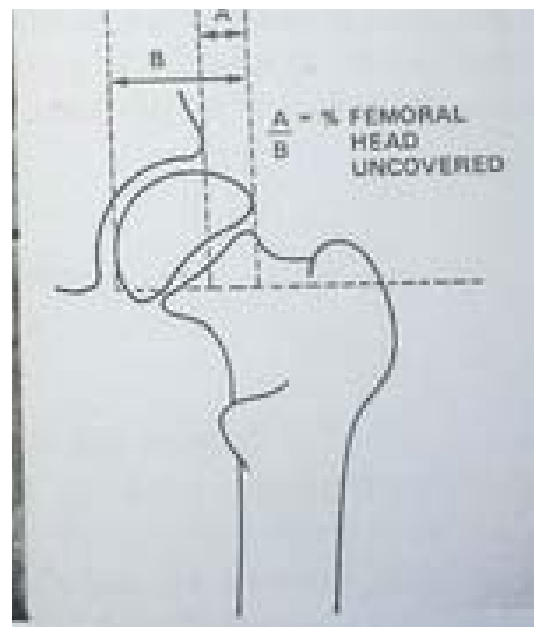
a year

2. Acetabular index

N=20°

3. Central edge angle of Wiberg

(N 20°)



Treatment

1. Physiotherapy No effect
2. Orthoses: No effect
3. Botox: No effect
4. Observe: Twice a year with X ray for 2-8 yrs:

5. At risk patients:	Abduction	Less than 45°
	Migration Index	More than 25%
	Acetabular Index	More than 30°

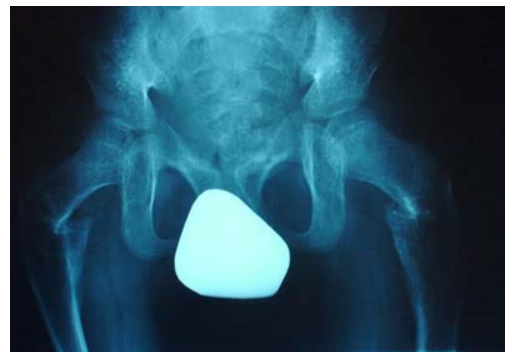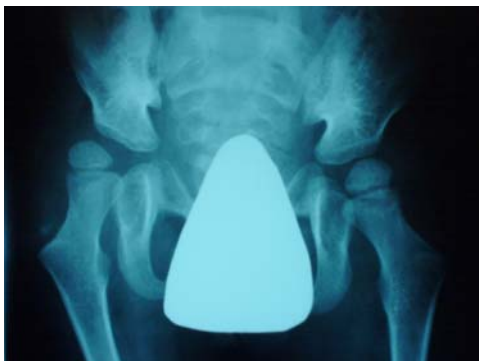6. Surgery for dislocation

Under 5 yrs: Release of adduction/flexion contraction release of the hip

1. Adductor: Transverse incision 2 cm distal to the inguinal crease; the fascia over the adductor longus is opened longitudinally. Finger dissection between adductor longus and Brevis. Anterior division of Obturator nerve runs anterior to adductor Brevis. Release tendinous part of the adductor longus. Release partly Brevis and aponeurotic origin of gracilis.
2. Psoas tendon is released through a separate bikini incision: dissection is between Rectus femoris and Tensor fascia lata. The iliopsoas tendon in the muscle identified taking care not to damage femoral nerve.

On stage comprehensive approach:

When gross bony changes present, in addition to soft tissue release a Varus Derotation osteotomy[VDR0] or a Pericapsular acetabuloplasty for spherical head or Shelf or Chiari for deformed head [Staheli's procedure] should be performed.



In mentally retarded with hip dislocation

1. Soft tissue releases, Anterior Obturator neurectomy,
2. Proximal femorectomy

Indication: Nonambulant; > 8 yrs, Painful hip dislocation

3. Castle procedure: Using an extraperiosteal dissection
The femoral head is resected distal to the lesser trochanter.
The gluteus is interposed
4. Modified Shands: Excision arthroplasty and a pelvic supporting valgus subtrochanteric osteotomy

Anteversion of femur causing scissoring

Femoral anteversion is said to be present when internal rotation is more than 60° and external rotation is less than 30°.

Anteverted femur gives an appearance of Coxa valga.

Varus correction: Aim between 110 or 120° (<110 = may itself contribute to coxa vara).
Need more of rotational correction than varus

Gait lab rule out muscular cause for anteversion. Confirm degree of anteversion with CT examination

Subtrochanteric corrective osteotomy or supracondylar osteotomy are equally good.
But when varus osteotomy is required, proximal osteotomy is preferred.

Scoliosis

Prognosis for scoliosis is poor and is not corrected by brace





Surgery improves sitting balance.





2 types: 1. Short curve or double curve. Treat like Idiopathic scoliosis


2. Long in lumbar or TL with Pelvic tilt: Luque Galverston technique

Appendix I

Primitive reflexes are reflex actions originating in the central nervous system that are exhibited by normal infants but not neurologically intact adults, in response to particular stimuli. These reflexes disappear or are inhibited by the frontal lobes as a child moves through normal child development.

REFLEX	NORMAL RESPONSE	ABNORMAL RESPONSE
Rooting and sucking	Newborns turn head in direction of stimulus, opens mouth, and begins to suck when cheek, lip, or corner of mouth is touched with finger or nipple. 	Weak or no response occurs with prematurity, neurologic deficit or injury, or central nervous system (CNS) depression secondary to maternal drug ingestion (eg. narcotics).
Extrusion	Newborn pushes tongue outward when tip of tongue is touched with finger or nipple. 	Continuous extrusion of tongue or repetitive tongue thrusting occurs with CNS anomalies and seizures.
Swallowing	Newborn swallows in coordination with sucking when fluid is placed on back of tongue.	Gagging, coughing, or regurgitation of fluid may occur, possibly associated with cyanosis
Moro	Bilateral symmetrical extension and abduction of all extremities when newborn is placed on back on flat surface. 	Asymmetrical response is seen with peripheral nerve injury (brachial plexus) or fracture of clavicle or long bone or arm or leg. No response occurs in cases of severe CNS injury.
Stepping	Newborn will step with one foot and then the other in walking motion when one foot is touched to flat surface. 	Asymmetrical response is seen with CNS or peripheral nerve injury or fracture of long bone of leg.

<p>Prone crawl</p>	<p>Newborn will attempt to crawl forward with both arms and legs when placed on abdomen or flat surface.</p> 	<p>Asymmetrical response is seen with CNS or peripheral nerve injury or fracture of long bone of leg.</p>
<p>Tonic neck or "fencing"</p>	<p>Extremities on side to which head is turned will extend, and opposite extremities will flex when newborn's head is turned to one side while resting. Response may be absent or incomplete immediately after birth.</p> 	<p>Persistent response after 4th month may indicate neurologic injury. Persistent absence seen in CNS injury and neurologic disorders.</p>
<p>Startle</p>	<p>Newborn abducts and flexes all extremities and may begin to cry when exposed to sudden movement or loud noise.</p> 	<p>Absence of response may indicate neurologic deficit or injury. Complete and consistent absence of response to loud noises may indicate deafness. Response may be absent or diminished during sleep.</p>
<p>Crossed Extension</p>	<p>Newborn's opposite leg will flex and then extend rapidly as if trying to deflect stimulus to other foot when placed in supine position; newborn will extend one leg in response to stimulus on bottom of foot.</p>	<p>Weak or absent response is seen with peripheral nerve injury or fracture of long bone.</p>
<p>Glabellar "blink"</p>	<p>Newborn will blink with first 4 or 5 taps to bridge of nose when eyes are open.</p>	<p>Persistent blinking and failure to habituate suggest neurologic deficit.</p>
<p>Palmar grasp</p>	<p>Newborn's finger will curl around object and hold on momentarily when finger is placed in palm of newborn's hand.</p> 	<p>Response is diminished in prematurity. Asymmetry occurs with peripheral nerve damage (brachial plexus) or fracture of humerus. No response occurs with severe neurologic deficit.</p>

Plantar Grasp	Newborn's toes will curl downward when a finger is placed against the base of the toes.		Diminished response occurs with prematurity. No response occurs with severe neurologic deficit.
Babinski sign			