

FOOT IN CEREBRAL PALSY

GAIT IN CEREBRAL PALSY

Group I True Equinus

Extended hip and knee

Equinus at ankle

II Jump Gait [commonest]

Equinus at ankle

Flexion at Hip and Knee

III Apparent Equinus

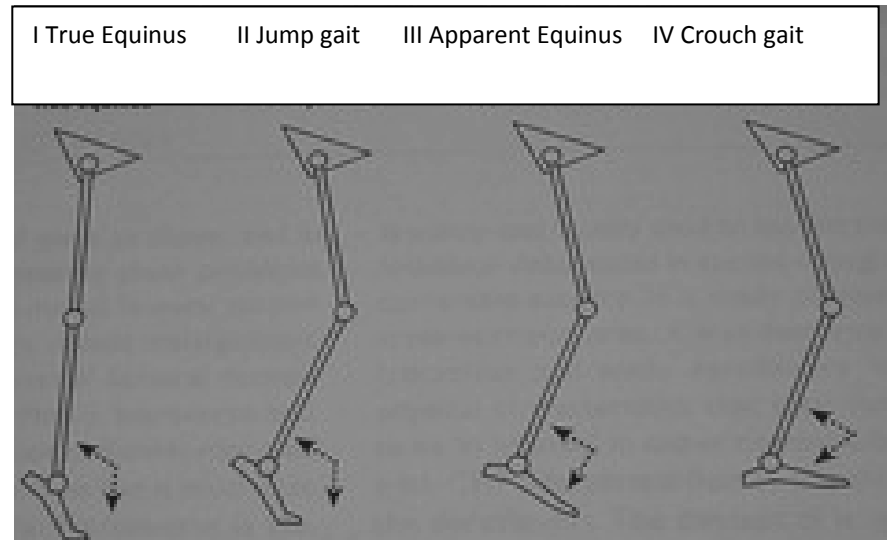
Plantigrade ankle

Flexion at knee and Hip

IV Crouch Gait

Calcaneus ankle

Flexed Hip and Knee



FACTS

1. Most need only Gastro aponeurotic release [in positive Silverskiold test]
2. Beware Achilles lengthening in Diplegic as this may worsen crouching gait
3. Achilles lengthening may be required in Hemiplegics
4. Percutaneous should be performed only in Primary release. In recurrent equinus, always open surgery is preferred.
5. Posterior capsulotomy of the ankle joint is rarely required in Cerebral Palsy and in muscular dystrophy
6. It has to noted that the varus deformity is easy to correct than valgus

Diplegic Hips is internal rotation and adducted

Knee is flexed and externally rotated

Foot is in valgus

Hemiplegia: Hip internal rotation

But the knee comes into extension in the stance

Foot assumes a varus posture.

EQUINUS DEFORMITY

Conservative treatment is often sufficient.

Stretching the soleus muscle 6 hours a day prevents contractures.

Brace: AFO: Swedish or Leaf or AFO with ankle joint

AFO with ground reaction: This brace has anterior shell near the upper part of tibia

It is indicated when there is weakness of quadriceps.

This prevents buckling during III rocker

SURGERIES

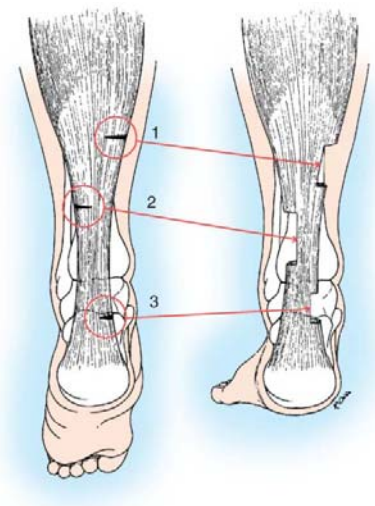
I. Percutaneous release of heel cord [White technique]

3 incomplete tenotomies

I Proximal 10 cm proximal to the calcaneum
[medial half is divided]

II Distal Near its insertion divide the anterior
two thirds of the tendon.

III Middle Lateral half is divided



Now forcefully dorsiflex the foot to lengthen the tendon

II Gastro release [When silverskiold test positive]

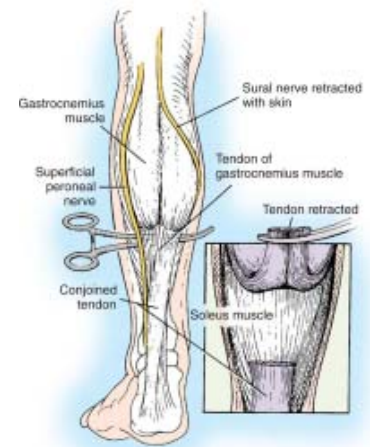
Strayer technique

The aponeuroses of the gastrocnemius is

divided transversely

Ankle is forcefully dorsiflexed

The foot is held in cast for 6 weeks



Vulpius technique

The aponeuroses of the gastrocnemius is divided with an inverted V-shaped incision.

Its distal part is allowed to retract distally but is not sutured to the soleus.

Baker's Procedure

Aponeurosis lengthening procedure

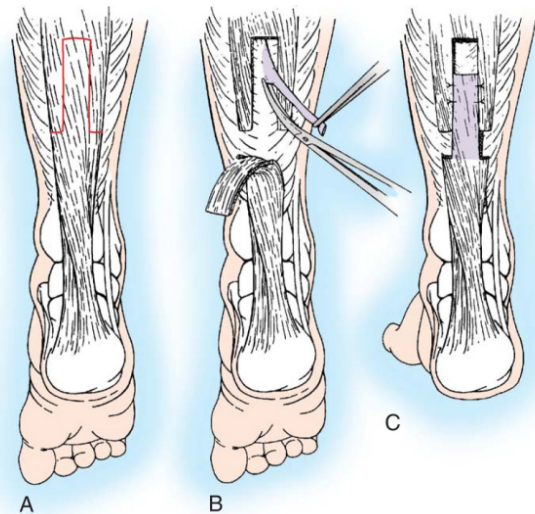
Aponeurosis of gastrocnemius is separated from soleus

Take care not to damage sural nerve

Divide fascia as shown and lengthen it

Foot in neutral position

Complications 5-10% recurrence of deformity following surgery



Gait Lab

1. Abnormal EMG of Tibialis Anterior

SPLATT Split tibialis anterior

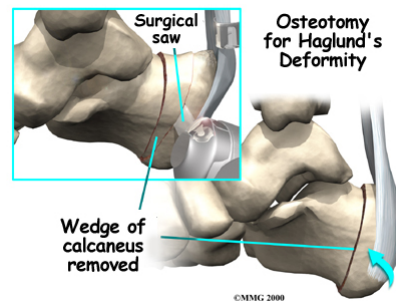
Split tendon is fixed to the lateral to peroneus brevis.

2. Abnormal Tibialis Posterior

Split tibialis posterior transfer to peroneus brevis

Calcaneal displacement osteotomy

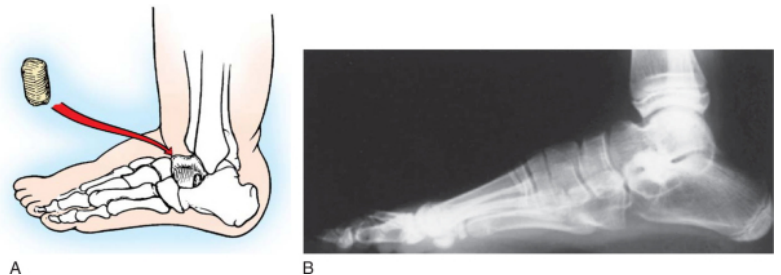
In fixed varus/valgus, a corrective osteotomy [Closed Dwyer] can be performed with or without a muscle-balancing procedure.



Open wedge osteotomies of the calcaneus is not recommend.

GRICE GREEN PROCEDURE

This was the procedure of choice for stabilizing the plano-valgus foot in cerebral palsy.



The bone grafts should be placed so that they lie at a right angle to the axis of motion of the subtalar joint and, as seen in a lateral roentgenogram of the foot, parallel to the weight-bearing axis of the leg, ankle, and foot.

Some use a screw from the neck. A long leg cast for 8 weeks and a short leg walking cast for 4 more weeks.

Now it is medial displacement calcaneal osteotomy with lateral column lengthening procedure, gaining the popularity. So that mobility of the subtalar joint is retained.

Dennyson and Fulford fusion of the subtalar joint

Obliquely incise the skin in line with the skin creases over the sinus tarsi.

Expose Extensor digiti brevis.

By sharp dissection excise the fat from the sinus tarsi with gouge remove the cortical bone from the apex of the sinus tarsi to expose cancellous bone on both the talar neck and the superior surface of the calcaneus

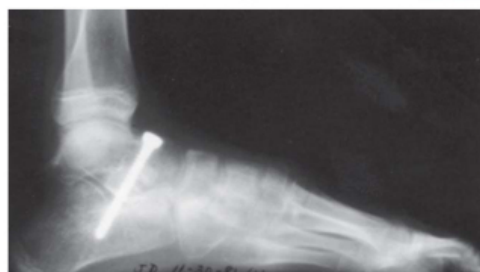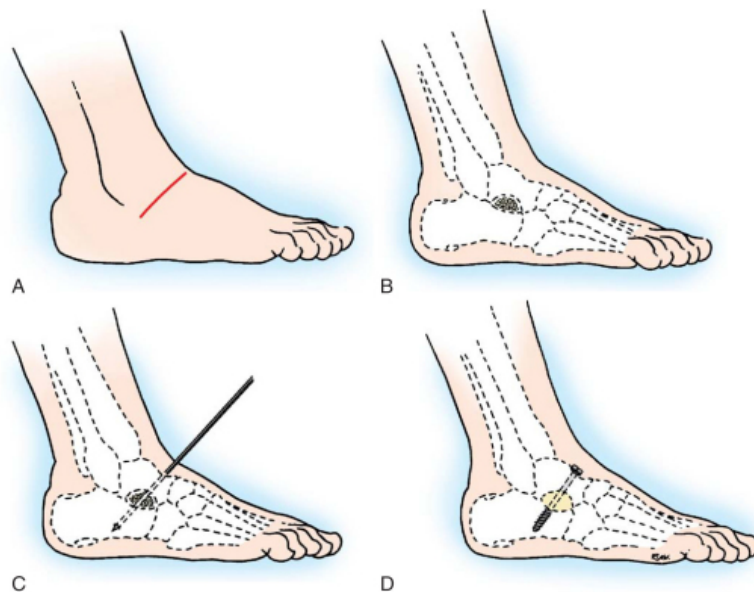
Dorsally expose the neck of the talus through a small separate skin incision

Hold the calcaneus in the corrected position and pass an awl from on top of the talus, through the talus, across the subtalar joint, and through the calcaneus.

Direct the awl posteriorly, inferiorly, and slightly laterally

Determine the desired length of a screw needed for fixation and insert a screw in the hole.

Remove chips of Cancellous bone from the iliac crest and pack them into the sinus tarsi and against the bone that has been denuded on the talus and calcaneus.



E

CALCANEAL OSTEOTOMY

Expose the lateral surface of the calcaneus through the lateral aspect of the heel, parallel to but inferior to the sural nerve and Peroneal longus.

The osteotomy protects the tendo-calcaneus superiorly and the plantar muscles, vessels, and nerves inferiorly.

Do not penetrate the periosteum on the medial side of the bone.

Once the osteotomy is complete the inferior fragment is displaced medially to align then insert a threaded Kirschner wire or screw