

FINGERS

I MALLET FINGER

Definition: Flexion at DIP and extension of PIP

Type I Tendon avulsion. Treat with splint

II Small bone avulsion fracture. Treat with splint

III $> 1/3^{\text{rd}}$ of the base of the distal phalanx.

Treatment

Soft tissue: splint for at least 6 weeks and gradually wean.

Open laceration: repair and use transarticular K wire

In Type III: At the middle third. screw or transosseous. Use K wire.

II SWAN NECK

Definition: Deformity results from PIP extension and DIP flexion

Pathogenesis

At PIP joint: Adhesion of lateral band
FDS rupture
Stretching of volar capsule

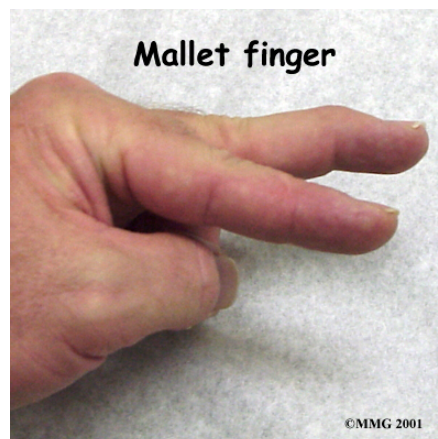At DIP joint: Mallet finger

Treatment

1. Intrinsic contracture

Clinical features: difficulty holding golf club or tennis racquet due to hyper-extension of MP.

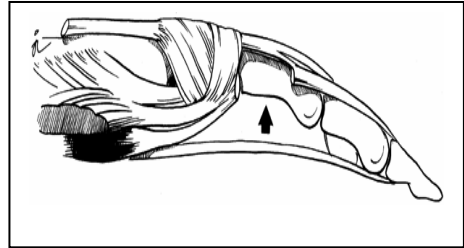
Diagnosis: Bunnel test positive, i.e. more flexion at PIPJ, with MPJ in flexion, than in extension.



A. Distal intrinsic release

Mild to moderate deformity: Distal release

For a moderate intrinsic contracture that limits PIP flexion, resect the oblique fibres and contiguous lateral bands on both the radial and ulnar sides of the finger through a dorsal incision.

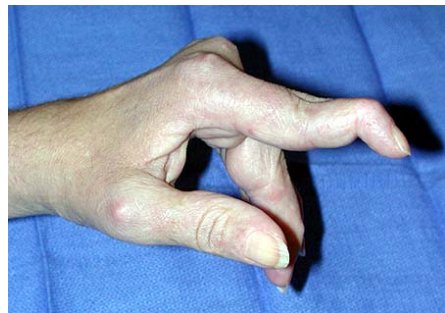

Severe Deformity: Proximal release

These MP flexion contractures result only from marked and severe intrinsic fibrosis. Release both distal oblique fibres and the proximal transverse fibres of the dorsal tendon mechanism that normally flex the MC joints.

2. Swan neck due to volar plate stretching

- a. Volar plate reconstruction
- b. FDS tenodesis [Littler]
- c. Reconstruction using one lateral band [Littler]



III BOUTONNIÈRE DEFORMITY

Definition: Flexion at PIP and Extension at DIP

Elson's test: from a 90 degree flexed position of the PIP joint over the edge of a table, patient is asked to extend fingers against resistance. The absence of extension force at the proximal joint and fixed extension at the distal joint are immediate signs of complete rupture of the central slip.

Pathogenesis

"Central slip" Problem

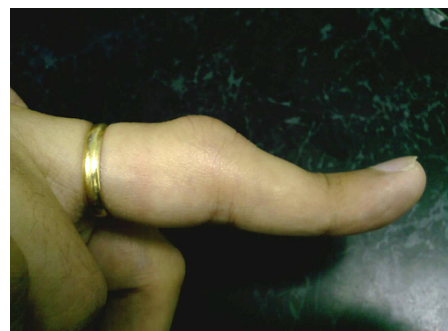PIP sprain

PIP dislocation [dorsal]

PIP joint fracture

Extensor tendon laceration

Extensor tendon loss



Chronic: Burns

Rheumatoid arthritis

Treatment

1. Open laceration of central slip: Open repair of the central slip. Transarticular K wire inserted to hold the joint in hyperextension for 2 weeks

2. Closed injury: Volar wooden spatula or Capener's spring splint for further 2 weeks

(It works for acute cases as well as deformities of more than 6 months duration)