

OSTEOCHONDROSIS

This refers to any of a group of disorders of one or more ossification centres in children, characterised by degeneration or aseptic necrosis followed by reossification.

It may occur at traction apophyses in children and may be associated with trauma.

It is pathologically similar to osteonecrosis in the adult.

Common osteochondroses (OC) include

Legg-Calvé-Perthes disease - OC of femoral head

Osgood-Schlatter disease - OC of tibial tuberosity

Sinding-Larsen-Johansen syndrome - OC of inferior patella

Sever's disease - OC of calcaneus

Köhler's disease - OC of tarsal navicular

Freiberg's infarction - OC of metatarsal head

Treatment

Asymptomatic: leave it alone

Symptomatic:

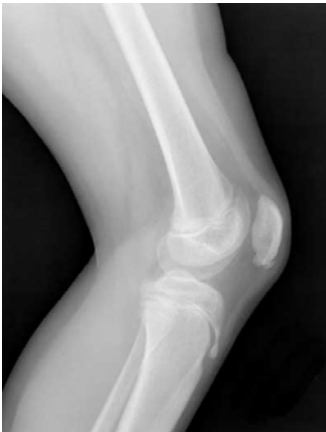- NSAID

- Cast

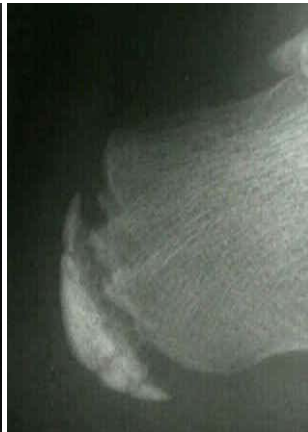- Activity modification

- Surgery: in selected cases of Perthes disease

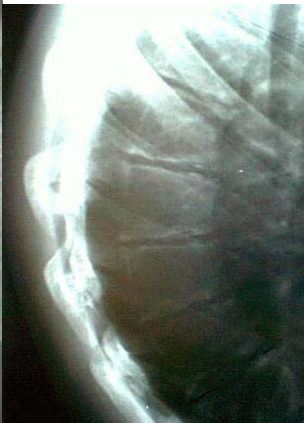Osgood Scatter's



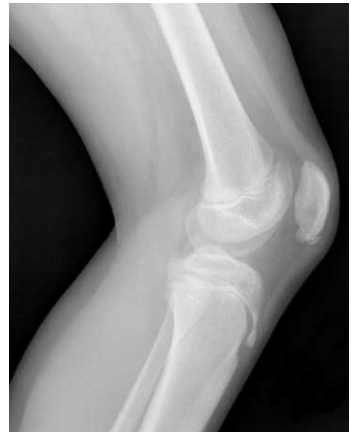Sever's



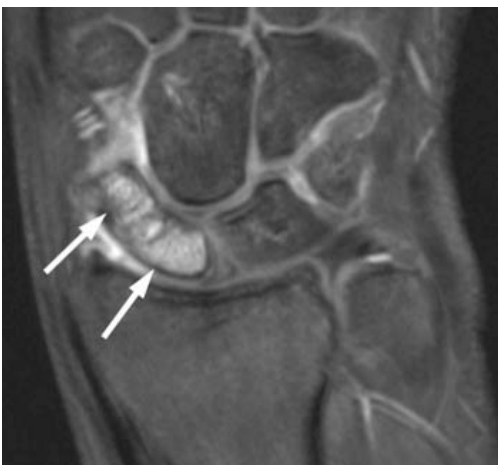Scheurmann's



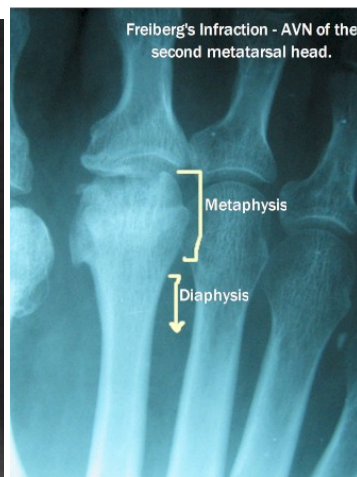
Siding Larsen



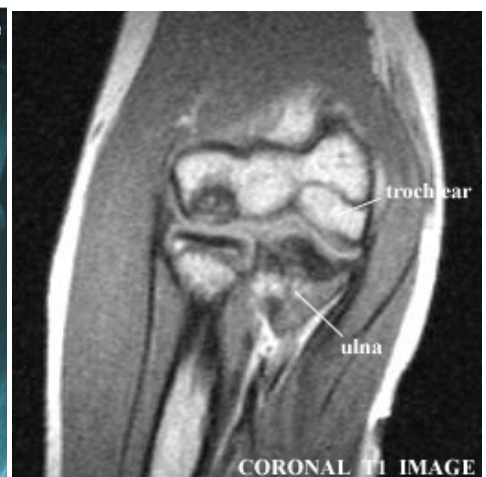Fraiser's



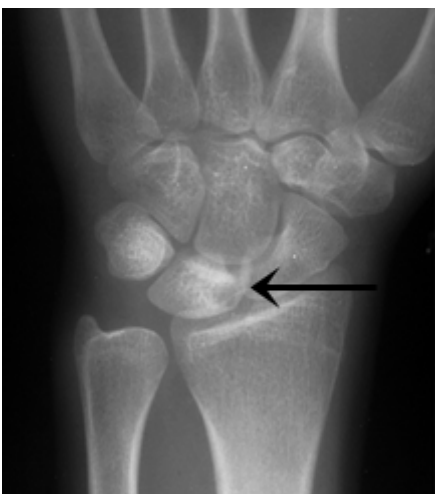Freiburg



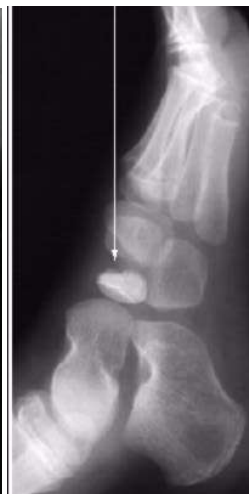Panner's



Kienboeck's



Kohler's



Perthes'

