

Abductor Tendon Tears of the Hip: Evaluation and Management

Paul F. Lachiewicz, MD

Abstract

The gluteus medius and minimus muscle-tendon complex is crucial for gait and stability in the hip joint. There are three clinical presentations of abductor tendon tears. Degenerative or traumatic tears of the hip abductor tendons, so-called rotator cuff tears of the hip, are seen in older patients with intractable lateral hip pain and weakness but without arthritis of the hip joint. The second type of tear may be relatively asymptomatic. It is often seen in patients undergoing arthroplasty for femoral neck fracture or elective total hip arthroplasty (THA) for osteoarthritis. The third type of abductor tendon dysfunction occurs with avulsion or failure of repair following THA performed through the anterolateral approach. Abductor tendon tear should be confirmed on MRI. When nonsurgical management is unsuccessful, open repair of the tendons with transosseous sutures is recommended. Good pain relief has been reported following endoscopic repair. Abductor tendon repair has had inconsistent results in persons with avulsion following THA. Reconstruction with a gluteus maximus muscle flap or Achilles tendon allograft has provided promising short-term results in small series.

From the Department of Orthopaedic Surgery, Duke University School of Medicine, and the Durham VA Medical Center, Durham, NC, and Chapel Hill Orthopedics Surgery & Sports Medicine, Chapel Hill, NC.

Dr. Lachiewicz or an immediate family member serves as a board member, owner, officer, or committee member of The Hip Society, the Orthopaedic Surgery & Trauma Society, and the Southern Orthopaedic Association; is a member of a speakers' bureau or has made paid presentations on behalf of Cadence and Zimmer; serves as a paid consultant to or is an employee of GlaxoSmithKline; and has received research or institutional support from Zimmer.

J Am Acad Orthop Surg 2011;19:385-391

Copyright 2011 by the American Academy of Orthopaedic Surgeons.

Lateral hip pain, or greater trochanteric pain syndrome, is a common clinical complaint that is often referred to as "greater trochanteric bursitis." This finding is more prevalent in women than men, with peak incidence between the fourth and sixth decades of life.¹ Typical clinical findings are chronic pain and tenderness over the proximal lateral aspect of the hip, usually directly on or anterior to the greater trochanter. Pain may be worsened by lying on the affected hip, walking, or climbing stairs. The patient may have a slight or moderate limp. Usually, passive hip range of motion is not restricted, but there may be a variable degree of weakness in side-lying abduction.

Typically, management begins with

short-term use of a nonsteroidal anti-inflammatory drug, physical therapy for stretching and strengthening, and judicious use of corticosteroid plus local anesthetic injection into the tender trochanteric bursa.² In the past several years, surgical exploration and MRI studies have elucidated the condition of chronic tears of the anterior tendons of the gluteus medius and minimus (ie, rotator cuff tear of the hip).

Anatomy

The gluteus medius muscle is a large curved fan-shaped muscle that originates from the anterior superior iliac spine and the outer edge of the iliac crest back to the posterior superior iliac spine. The origin is approxi-

Figure 1

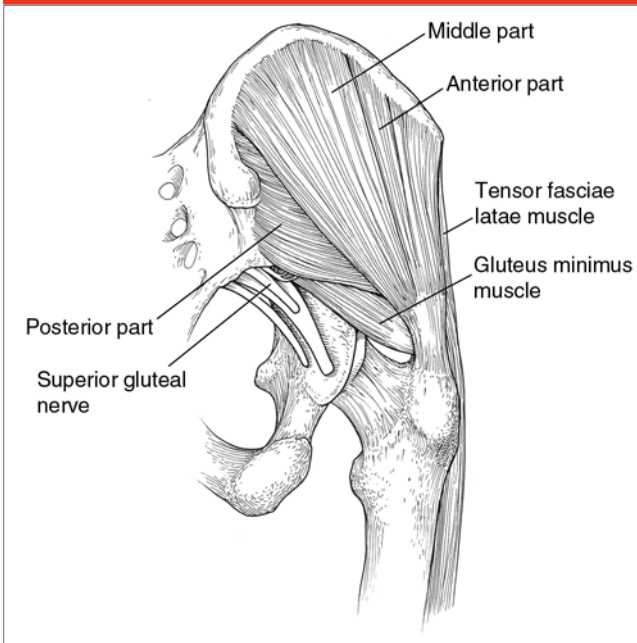


Illustration of the lateral hip musculature demonstrating the three parts of the gluteus medius muscle (ie, anterior, middle, posterior) in relation to the hip joint. (Adapted with permission from Gottschalk F, Kourosh S, Leveau B: The functional anatomy of tensor fasciae latae and gluteus medius and minimus. *J Anat* 1989;166:179-189.)

Figure 2

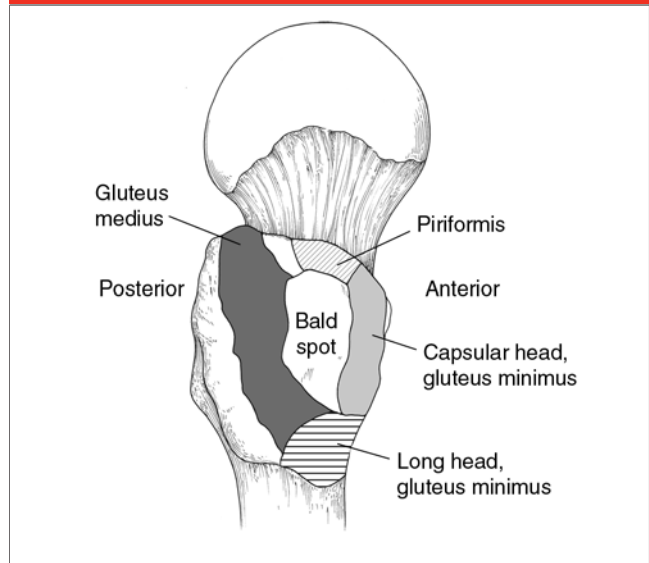


Illustration of a superolateral view of the right proximal femur in a cadaveric specimen demonstrating the attachment sites of the gluteus medius tendon, the two heads of the gluteus minimus muscle, and the piriformis muscle, as well as the bald spot of the greater trochanter. (Adapted with permission from Robertson WJ, Gardner MJ, Barker JU, Boraiah S, Lorich DG, Kelly BT: Anatomy and dimensions of the gluteus medius tendon insertion. *Arthroscopy* 2008;24[2]: 130-136.)

mately 1 cm broad and is limited to the iliac crest. The muscle fibers are separated from the iliac periosteum by loose fibrous tissue. The muscle has three distinct portions of equal volume—anterior, middle, and posterior—which are innervated by the superior gluteal nerve (Figure 1). The fibers of the anterior and middle parts are vertically oriented and have a vertical pull, and they aid in initiating hip abduction.³ The anterior part is also a primary pelvic rotator. The posterior part of the gluteus medius is horizontal, running parallel to the femoral neck. It stabilizes the hip joint in gait from heel strike to full stance. The gluteus minimus muscle originates from the anterior inferior iliac spine to the posterior inferior iliac spine along the middle gluteal line. The fibers of the gluteus mini-

mus are also horizontally oriented in relation to the femoral neck, and they run parallel to it. The gluteus minimus also stabilizes the hip joint during the mid and late stages of the gait cycle.³

The anatomy of the attachment sites of the gluteus medius tendon at the greater trochanter is much more complex than previously realized. A recent anatomic study indicated that the gluteus medius tendon inserts onto the greater trochanter by two distinct attachment sites—the superoposterior facet and the lateral facet⁴ (Figure 2). The posterior gluteus medius fibers insert onto the superoposterior facet of the greater trochanter. Most of the central portion and all of the anterior portion of the gluteus medius insert into the lateral facet.

The superoposterior facet has an approximately circular shape, with a radius of 8.5 mm and a total surface area of 196.5 mm². The lateral facet has an approximately rectangular shape, with a larger surface area (438 mm²). The gluteus minimus tendon inserts into both the hip capsule (ie, capsular head) and the lateral facet beneath the gluteus medius tendon (ie, long head). There is a bald area on the greater trochanter between the capsular head of the gluteus minimus and the lateral facet insertion of the gluteus medius.

Differential Diagnosis

The differential diagnosis of lateral hip pain caused by chronic abductor tendon tear includes hip osteoarthri-

tis (OA), occult fracture of the proximal femur, neuropathy or iatrogenic injury of the superior gluteal nerve, lower lumbar spondylosis, and lumbar spinal stenosis. Hip OA is usually accompanied by limited range of motion. With occult fracture of the proximal femur, the patient is unable to perform a resisted straight-leg raise while lying supine. Radiographs are helpful in the diagnosis of hip OA and hip fracture.

With lumbar spondylosis and spinal stenosis, the pain pattern is more radicular, rather than localized to the greater trochanter. However, the patient may present with a limp and hip abductor weakness. Neuropathy of the superior gluteal nerve is rare and may be associated with diabetes mellitus or rheumatoid arthritis. The patient with a history of prior hip surgery performed through the anterolateral or another approach or a revision arthroplasty may present with iatrogenic injury of the superior gluteal nerve.

Suggested treatment for the patient with lateral hip pain and tenderness over the anterolateral greater trochanter includes initial use of nonsteroidal anti-inflammatory medications and physical therapy for the abductor muscles. If this is not helpful, management with one or two corticosteroid injections into the greater trochanteric bursa should be attempted. MRI may be considered for patients with severe pain and hip abductor weakness that is not responsive to these nonsurgical measures. This treatment algorithm is not evidence-based.

Imaging

In patients with chronic tears of the abductor tendon, plain radiographs are usually unremarkable. However, they may illustrate sclerosis, an irregular border, or osteophytes at the an-

terior edge of the greater trochanter.⁵ Large osteophytes of the greater trochanter may be associated with the presence of small cysts. These findings are sometimes seen in patients with primary OA of the hip.

Diagnosis of gluteus medius tendon tears using MRI was described in a group of six women with no history of trauma or underlying medical problems (mean age, 70 years).⁶ Thickened appearance of the tendon (ie, increased signal intensity on T2-weighted images) was found to be diagnostic of partial-thickness tear. Full-thickness tear consisted of discontinuity of tendon fibers with or without muscle retraction or atrophy. In a study of 250 patients with pain of the lateral hip, buttock, or groin, MRI demonstrated tendinosis or tears of the gluteus medius and minimus tendons in 35 (14%).⁷ A thickened tendon and increased signal intensity on T2-weighted images without discontinuity was indicative of tendinosis. Focal discontinuity indicated partial tear, and complete tear was diagnosed only with retraction of the torn tendon. A study of 74 hips in 45 patients indicated 91% accuracy of MRI in diagnosing abductor tendon tears.⁸ Identification of an area of hyperintensity on the T2-weighted image superior to the greater trochanter had the highest sensitivity and specificity (73% and 95%, respectively) (Figure 3).

MRI has also been used to assess the abductor tendons and muscles after total hip arthroplasty (THA). In one study of eight patients with clinical prosthesis failure after THA performed through the anterolateral approach, abductor muscle avulsion was noted on MRI and confirmed at surgical exploration in two women.⁹ Another prospective study used MRI to evaluate 25 patients with and 39 patients without trochanteric pain and abductor weakness following THA performed through the lateral

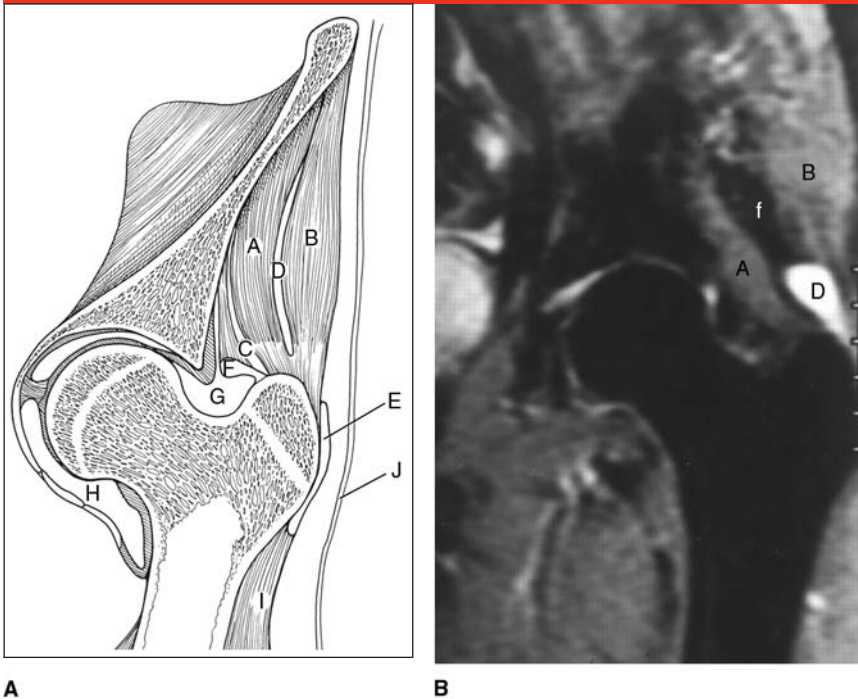
transgluteal approach.¹⁰ Symptomatic patients had significantly more defects in the gluteus minimus and medius tendons ($P < 0.001$). Fatty atrophy was seen in the anterior two thirds of the gluteus minimus muscle in both groups, but fatty atrophy of the gluteus medius muscle was present only in the symptomatic patients.

Clinical Scenarios and Management

There are three clinical scenarios of abductor tendon tear of the hip: chronic, nontraumatic tear of the anterior fibers of the gluteus medius tendon; abductor tendon tears found coincidentally at the time of open surgical management of femoral neck fracture or elective THA for OA; and abductor tendon avulsion following THA performed through an anterolateral or transgluteal approach.

The first type, chronic, nontraumatic tear of the anterior fibers of the gluteus medius tendon, was first described by Kagan¹¹ in seven patients with so-called trochanteric bursitis that was unresponsive to nonsurgical management. Kagan¹¹ referred to this disorder as “rotator cuff tear of the hip.” The mean age of the five women and two men in the study was 69 years (range, 52 to 81 years). Symptoms included lateral hip pain, local tenderness, and weakness of hip abduction lasting 1 month to 10 years. Hip radiographs were normal in all patients. MRI illustrated fluid in the trochanteric bursa as well as tears of the gluteus medius tendon, either from the bone or within the substance of the tendon. These tears were repaired with heavy sutures drilled through bone. In most cases, the fascia lata was left open to prevent impingement of the fascia over the suture line. At an average follow-up of 41.6 months

Figure 3



A, Illustration of a hip coronal section at the level of the mid greater trochanter demonstrating normal abductor muscles and tendons. **B**, T2-weighted coronal magnetic resonance image of the left hip in a 72-year-old woman with a surgically proven full-thickness tear of the abductor tendon. There is a 2-cm area of high signal intensity superior to the greater trochanter (D). The tendon tear is not directly visualized. A = gluteus minimus muscle, B = gluteus medius muscle, C = subgluteus minimus bursa, D = subgluteus maximus bursa, E = intermuscular fat, F = hip joint capsule, G = superior neck recess of hip joint, H = inferior neck recess of hip joint, I = vastus lateralis muscle, J = fascia lata. (Adapted with permission from Cvitanic O, Henzie G, Skezas N, Lyons J, Minter J: MRI diagnosis of tears of the hip abductor tendons [gluteus medius and gluteus minimus]. *AJR Am J Roentgenol* 2004;182[1]:137-143.)

(range, 21 to 60 months), all patients had pain relief, and only one had persistent weakness.

Recently, the results of two larger series of abductor tendon tears were reported. Davies et al¹² described 24 patients (22 women, 2 men) with a mean age of 67 years who underwent repair with **transosseous sutures or suture anchors**. All but one patient had improvement in hip pain and muscle strength at a minimum 2-year follow-up. **Walsh** et al¹³ reported the results of surgical repair in 89 patients treated from 2000 through 2008. At 6-month follow-up, 88% had minimal or no pain.

The most frequent complication was deep vein thrombosis (6%). Abductor tendon tears may also occur in younger patients. Fisher et al¹⁴ reported sequential **spontaneous** ruptures of the gluteus medius and minimus tendons in a 42-year-old woman with no history of trauma or any predisposing condition.

Rotator cuff tear of the hip should be suspected in patients with lateral hip pain and weakness that is unresponsive to nonsurgical care. When a tear is visible on MRI, surgical repair should be considered early, before the onset of serious fatty muscle atrophy. Endoscopic repair of a gluteus

medius tendon tear with metal suture anchors has been reported in 10 patients with a mean age of 50.4 years (range, 33 to 66 years).¹⁵ At a mean follow-up of 25 months (range, 19 to 38 months), all 10 patients had complete pain relief and excellent abductor muscle strength.

The second clinical scenario involves abductor tendon tear found coincidentally at the time of either open surgical management of femoral neck fracture or elective THA to manage OA. Bunker et al⁵ studied 50 consecutive patients undergoing arthroplasty for a femoral neck fracture (mean age, 83.5 years; range, 56 to 98 years). Eleven patients were found to have a tear of the anterior one third of the gluteus medius and minimus tendons (22%). The tear was large (2 to 3 cm) in six patients, small (0.5 to 1 cm) in two, and interstitial in three. The tear presented as a circular or oval defect in the common insertional tendon of the gluteus medius and minimus (Figure 4). The trochanteric bursa was filled with fluid, and the surface of the bare greater trochanter was often eburnated and sclerotic, with some osteophytes present. Bunker et al⁵ recommended excision of trochanteric osteophytes and decortication of sclerotic bone prior to repair with three intraosseous sutures. They did not state whether the fascia lata was repaired, nor did they report the results of repair.

In a **prospective study of 176 consecutive patients** who underwent elective THA using the direct lateral approach for OA, Howell et al¹⁶ reported that **34 patients had degenerative pathology of the abductor mechanism (20%)**. This finding was seen in 22 of 99 women and 12 of 77 men (mean age, 68 and 70 years, respectively). All persons with an abductor tendon tear were significantly older than those without a tear. There was no significant difference

Figure 4

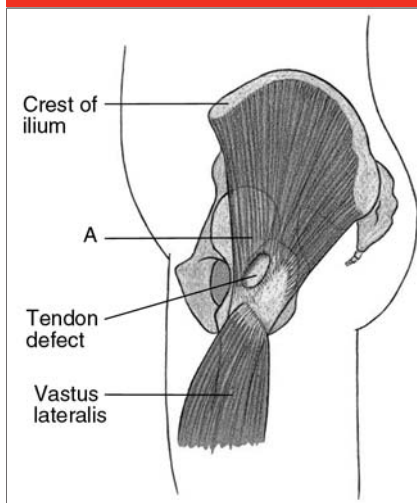


Illustration demonstrating the typical site of a tear of the gluteus medius tendon. A = tendon of the anterior one third of the gluteus medius and gluteus minimus. (Adapted with permission from Bunker TD, Esler CN, Leach WJ: Rotator-cuff tear of the hip. *J Bone Joint Surg Br* 1997;79[4]:618-620.)

in mean body mass index in women and men with or without a tear. Tear size ranged from <1 to 12 cm^2 , and 21 of 34 patients had a tear of $<1 \text{ cm}^2$ involving the hip capsule and abductor tendon. Only five patients had a tear $>3 \text{ cm}^2$. Twenty-five patients with tears of the abductor tendon retrospectively recalled an acute exacerbation of pain before arthroplasty (74%). These authors theorized that the pathologic process was ischemia with resultant degenerative changes within the capsule and abductor tendons, eventually resulting in a tear. The method of repair and the results of arthroplasty were not reported.

In five women with tears $>1 \text{ cm}^2$, this author used a posterior approach to the hip combined with abductor tendon repair using transosseous sutures after decortication of the greater trochanter. The fascia lata was routinely repaired. The patients were allowed to bear weight as toler-

ated, but they used a walker for 6 weeks to protect the repair. At follow-up of 1 to 5 years, four of the five women had complete pain relief and no limp or a slight limp. One patient had chronic lateral hip pain.

Surgeons should consider identification by direct inspection and palpation of the tendon, and probably repair abductor tendon tear in all patients undergoing elective THA, especially in older women with a recent exacerbation of pain preoperatively.

The third clinical scenario involves abductor tendon avulsion after THA performed through an anterolateral or transgluteal approach. The anterolateral (ie, direct lateral, transgluteal) approach popularized by Hardinge is favored by many surgeons in North America and Europe because it offers extensive exposure, and the reported rate of dislocation is low.^{17,18} The two potential complications with this approach are injury to the superior gluteal nerve or vessels and abductor insufficiency, with persistent pain, limp, and, in some cases, anterior dislocation as the result of dehiscence of the abductor repair.¹⁸ In one study, 24 of 543 patients had persistent lateral trochanteric pain that began at a mean of 19 months after primary THA (range, 6 to 43 months).¹⁹ This pain was significantly more common in females than in males and in patients who underwent a direct lateral approach rather than a posterior approach ($P < 0.04$ and $P < 0.01$, respectively).

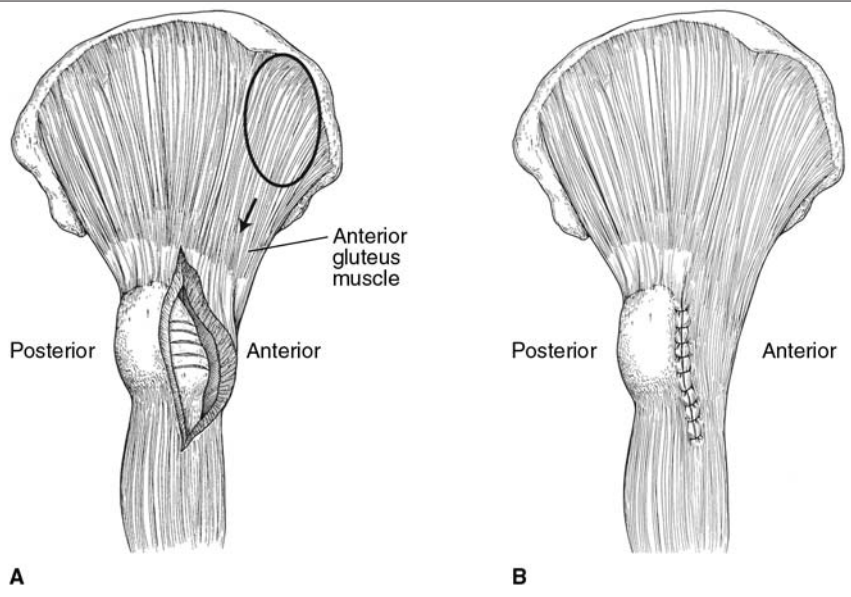
In one prospective study of 97 consecutive THAs performed through the direct lateral approach, the abductors were repaired with interrupted No. 0 PDS (polydioxanone; Johnson & Johnson, New Brunswick, NJ) sutures and reinforced with an osteosuture using a Mersilene band (B. Braun, Melsungen AG, Melsungen, Germany).²⁰ During closure, each side of the suture line was

marked with several metal marker sutures, and the distances between the metal sutures were measured on sequential radiographs. At 2 weeks postoperatively, a separation $>1 \text{ cm}$ between the markers was seen in 23 of 97 hips. At 2 months, the separation was $>1 \text{ cm}$ in 41 hips, $>2 \text{ cm}$ in 21, and $>3 \text{ cm}$ in 2. At 1-year follow-up, separation of $>1 \text{ cm}$ was seen in 54 hips, $>2 \text{ cm}$ in 21, and $>3 \text{ cm}$ in 6. However, the only statistical correlation was between separation $>2.5 \text{ cm}$ and limp, and there was no correlation between separation and pain or function.

In a review of the Mayo Clinic Joint Replacement Database, Weber and Berry²¹ reported the results of repair of abductor avulsion in nine patients at a mean follow-up of 4.8 years. Prior to reoperation, all patients had a severe limp, eight used a walking support full time, and five had moderate or severe pain. Repair consisted of freshening the bony bed on the trochanter followed by repair with heavy nonabsorbable braided sutures through drill holes. Postoperatively, there was modest improvement in limp (five of nine improved) and use of walking support (six used no support). However, only one of five patients with moderate or severe pain was improved. The authors suggested that the best indications for abductor repair are severe abductor weakness and hip instability and that significant preoperative pain is less likely to be decreased.

In another study, MRI was used to evaluate the results of late repair of abductor avulsion in 12 patients who underwent THA via the transgluteal approach.²² The diagnosis of avulsion was made on the basis of persistent trochanteric pain, tenderness, a limp despite physical therapy, and weak hip abduction in the lateral position. The repair was performed by debriding the greater trochanter to a bleeding surface and affixing the

Figure 5



A, Illustration demonstrating a defect caused by dehiscence of the common aponeurosis closure after an anterolateral (ie, transgluteal) approach to the hip. To close the defect, the anterior gluteus medius muscle is advanced (arrow). When necessary, adhesions are released from the ilium (oval area). The exposed greater trochanter is decorticated to obtain a bleeding surface. **B**, Illustration demonstrating nonabsorbable transosseous sutures holding the tendonous tissue to the greater trochanter. The vastus lateralis fascia and the edges of the repaired aponeurosis have been repaired, as well. (Redrawn with permission from Miozzari HH, Dora C, Clark JM, Nötzli HP: Late repair of abductor avulsion after the transgluteal approach for hip arthroplasty. *J Arthroplasty* 2010;25[3]:450-457, e1.)

Figure 6

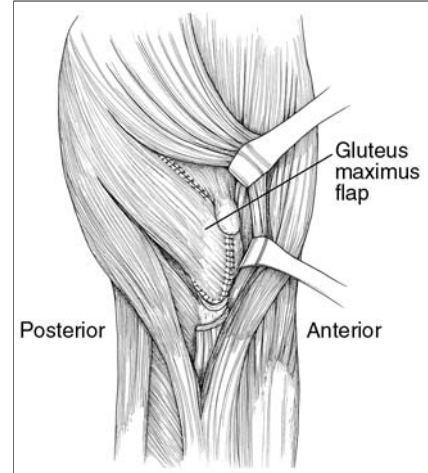


Illustration demonstrating posterior gluteus maximus flap transfer to reconstruct the abductor muscle deficiency resulting from nonunion of the greater trochanter. A 6- to 10-cm posterior gluteus maximus flap is transferred into an abductor defect and sutured to the anterior capsule of the hip joint, the remains of the quadratus femoris, and the posterior edge of the gluteus medius. (Redrawn with permission from Whiteside LA, Nayfeh T, Katerberg BJ: Gluteus maximus flap transfer for greater trochanter reconstruction in revision THA. *Clin Orthop Relat Res* 2006;453:203-210.)

conjoint insertion to the trochanter with three to five nonabsorbable No. 3 transosseous sutures (Ethibond; Ethicon, Somerville, NJ) (Figure 5). Partial weight bearing on two crutches was maintained for 8 weeks. All 12 patients were evaluated preoperatively with MRI, and 10 had a postoperative MRI. The remaining two patients underwent subsequent revision surgery. At 1-year follow-up, 9 of the 12 patients were satisfied with the result and had improved pain scores. However, four patients experienced a persistent limp. MRI examination postoperatively demonstrated an intact repair in six patients and failure in four. The fatty degeneration seen in the anterior gluteus medius muscle

on MRI did not reverse in any patient; this finding may explain the lack of improvement in abductor muscle strength.

Two reconstruction techniques have been described. Whiteside et al²³ reported the results of a new technique using a posterior gluteus maximus muscle flap transfer to manage osteolytic destruction of the greater trochanter with abductor insertion deficiency. They used this technique in five patients and left the trochanter unrepaired in five other patients. A 6- to 10-cm posterior flap of gluteus maximus muscle is created, which is transferred into the abductor-greater trochanteric defect and sutured into the anterior capsule of the hip joint (Figure 6). The pa-

tient is kept partial weight bearing with two supports, and abduction exercises are prohibited for 8 weeks. In this study, the patients treated with a gluteus maximus flap had less pain, reduced limp, and reduced use of walking supports than did patients who did not undergo this procedure.²³ The results of this technique are promising, but they require confirmation by other studies.

Fehm et al²⁴ reported on the use of Achilles tendon allograft to repair massive abductor tear after THA in seven patients with lateral hip pain and abductor weakness (mean Harris hip score, 34.7). The calcaneal bone block was fastened to the greater trochanter, and the allograft

tendon was woven into the abductor muscle-tendon complex. At a minimum 2-year follow-up, all patients demonstrated improvement in pain score and function (mean Harris hip score, 85.9). Additional studies with longer follow-up are required to confirm the utility of and success with this technique.

Summary

Tear of the abductor tendon complex (ie, rotator cuff tear of the hip) is a relatively infrequent cause of lateral trochanteric hip pain. However, it should be considered in all patients, particularly older women, with lateral hip pain and abductor weakness that are unresponsive to nonsurgical management. MRI has great diagnostic sensitivity and specificity, with increased T2-weighted signal intensity at the greater trochanter. Repair of the torn abductor tendons to a bleeding trochanteric bed with transosseous sutures typically provides good pain relief as well as improved strength and function. Coincidental abductor tendon tears are found with relative frequency in older patients, usually women with femoral neck fractures or OA. These patients do well after arthroplasty and concomitant repair. Late avulsion of the abductor tendons after THA performed through the anterolateral or transgluteal approach is relatively uncommon; however, it is a cause of lateral trochanteric pain, weakness, and limp requiring walking supports. Repair is successful in approximately three quarters of patients, with demonstrated pain relief but variable improvement in strength. Small series have reported promising results following reconstruction of the abductor tendon complex with either a gluteus maximus muscle flap or an Achilles tendon allograft.

References

Evidence-based Medicine: Reference 2 is level V expert opinion. All other references are level IV studies.

References printed in **bold type** are those published in the past 5 years.

- Bird PA, Oakley SP, Shnier R, Kirkham BW: Prospective evaluation of magnetic resonance imaging and physical examination findings in patients with greater trochanteric pain syndrome. *Arthritis Rheum* 2001;44(9):2138-2145.
- Dougherty C, Dougherty JJ: Managing and preventing hip pathology in trochanteric pain syndrome. *The Journal of Musculoskeletal Medicine* 2008;25:521-523.
- Gottschalk F, Kourosh S, Leveau B: The functional anatomy of tensor fasciae latae and gluteus medius and minimus. *J Anat* 1989;166:179-189.
- Robertson WJ, Gardner MJ, Barker JU, Boraiah S, Lorich DG, Kelly BT: Anatomy and dimensions of the gluteus medius tendon insertion. *Arthroscopy* 2008;24(2):130-136.
- Bunker TD, Esler CN, Leach WJ: Rotator-cuff tear of the hip. *J Bone Joint Surg Br* 1997;79(4):618-620.
- Chung CB, Robertson JE, Cho GJ, Vaughan LM, Copp SN, Resnick D: Gluteus medius tendon tears and avulsive injuries in elderly women: Imaging findings in six patients. *AJR Am J Roentgenol* 1999;173(2):351-353.
- Kingzett-Taylor A, Tirman PF, Feller J, et al: Tendinosis and tears of gluteus medius and minimus muscles as a cause of hip pain: MR imaging findings. *AJR Am J Roentgenol* 1999;173(4):1123-1126.
- Cvitanic O, Henzie G, Skezas N, Lyons J, Minter J: MRI diagnosis of tears of the hip abductor tendons (gluteus medius and gluteus minimus). *AJR Am J Roentgenol* 2004;182(1):137-143.
- Twair A, Ryan M, O'Connell M, Powell T, O'Byrne J, Eustace S: MRI of failed total hip replacement caused by abductor muscle avulsion. *AJR Am J Roentgenol* 2003;181(6):1547-1550.
- Pfirmsmann CW, Notzli HP, Dora C, Hodler J, Zanetti M: Abductor tendons and muscles assessed at MR imaging after total hip arthroplasty in asymptomatic and symptomatic patients. *Radiology* 2005;235(3):969-976.
- Kagan A II: Rotator cuff tears of the hip. *Clin Orthop Relat Res* 1999;(368):135-140.
- Davies JF, Geiger PB, Davies JA, Yahr D, Kroner JM: Results of open surgical treatment of abductor tendon tears of the hip. *76th Annual Meeting Proceedings*. Rosemont, IL, American Academy of Orthopaedic Surgeons, 2009, p 463.
- Walsh M, Walsh NA, Walton J, Millar N: Surgical repair of the abductor mechanism of the hip. *76th Annual Meeting Proceedings*. Rosemont, IL, American Academy of Orthopaedic Surgeons, 2009, p 463.
- Fisher DA, Almand JD, Watts MR: Operative repair of bilateral spontaneous gluteus medius and minimus tendon ruptures: A case report. *J Bone Joint Surg Am* 2007;89(5):1103-1107.
- Voos JE, Shindle MK, Pruett A, Asnis PD, Kelly BT: Endoscopic repair of gluteus medius tendon tears of the hip. *Am J Sports Med* 2009;37(4):743-747.
- Howell GE, Biggs RE, Bourne RB: Prevalence of abductor mechanism tears of the hips in patients with osteoarthritis. *J Arthroplasty* 2001;16(1):121-123.
- Hardinge K: The direct lateral approach to the hip. *J Bone Joint Surg Br* 1982;64(1):17-19.
- Mulliken BD, Rorabeck CH, Bourne RB, Nayak N: A modified direct lateral approach in total hip arthroplasty: A comprehensive review. *J Arthroplasty* 1998;13(7):737-747.
- Iorio R, Healy WL, Warren PD, Appleby D: Lateral trochanteric pain following primary total hip arthroplasty. *J Arthroplasty* 2006;21(2):233-236.
- Svensson O, Sköld S, Blomgren G: Integrity of the gluteus medius after the transgluteal approach in total hip arthroplasty. *J Arthroplasty* 1990;5(1):57-60.
- Weber M, Berry DJ: Abductor avulsion after primary total hip arthroplasty: Results of repair. *J Arthroplasty* 1997;12(2):202-206.
- Miozzari HH, Dora C, Clark JM, Nötzli HP: Late repair of abductor avulsion after the transgluteal approach for hip arthroplasty. *J Arthroplasty* 2010;25(3):450-457, e1.
- Whiteside LA, Nayfeh T, Katerberg BJ: Gluteus maximus flap transfer for greater trochanter reconstruction in revision THA. *Clin Orthop Relat Res* 2006;453:203-210.
- Fehm MN, Huddleston JI, Burke DW, Geller JA, Malchau H: Repair of a deficient abductor mechanism with Achilles tendon allograft after total hip replacement. *J Bone Joint Surg Am* 2010;92(13):2305-2311.