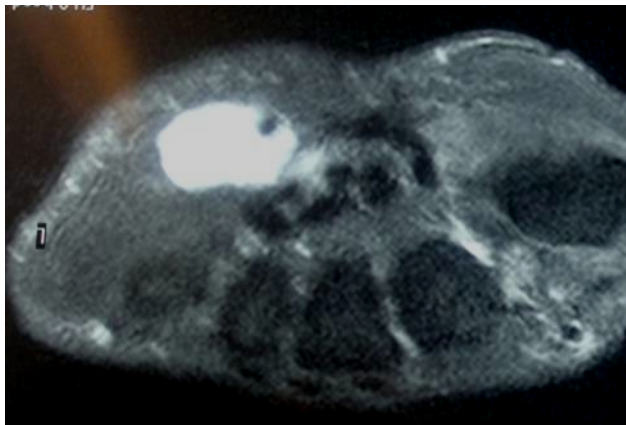
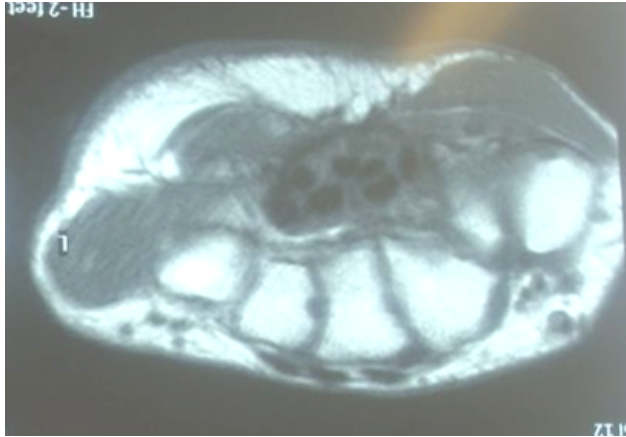


Case 1



44-year-old midwife presented with intermittent pins and needles in the little and ring fingers with blanching. Symptoms were exacerbated by cold exposure.

Your diagnosis

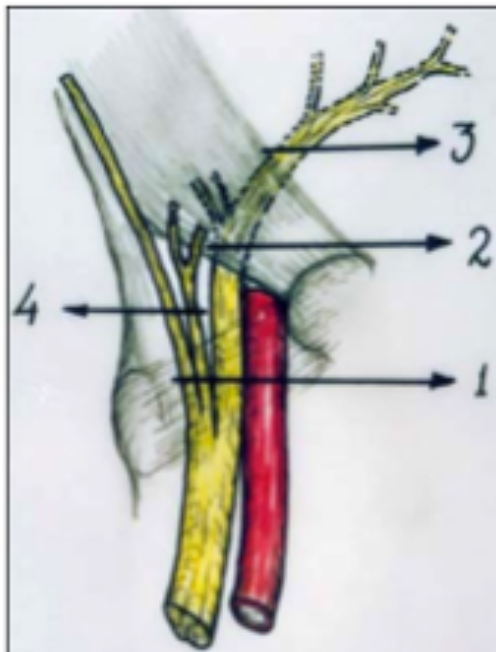
Diagnosis Hypothenar syndrome

Hypothenar hammer syndrome is due to posttraumatic vascular insufficiency of the hand caused by repetitive compression or blunt trauma to the hypothenar eminence injuring the terminal ulnar artery or proximal superficial palmar arch. A dull ache and tenderness with insidious progression of ischemic symptoms for weeks to months are typical. Ischemic symptoms and signs include a cold sensation, paresthesias, blanching, cyanosis, and even atrophic ulceration.

ANATOMY

Guyon's canal is bounded medially by the pisiform, laterally by the hook of the hamate, floor by flexor retinaculum and the roof by the volar carpal ligament. The contents medial to lateral are ulnar nerve, ulnar artery and ulnar vein.

Anatomy of the Guyon's canal



1. Palmar carpal ligament
2. Transverse carpal ligament
3. Deep motor ulnar branch
4. Superficial sensory ulna br

Vascularity of the palm is both abundant and redundant, with deep and superficial palmar arches. At Guyon's canal, the ulnar artery branches to form the deep palmar arch coursing to the radial wrist.

The deep palmar arch is described as complete when the ulnar portion connects to deep palmar portion of the radial artery.

As the ulnar artery exits Guyon's canal, the distal portion of the artery contributes to the superficial palmar arch, with the radial side being completed either by joining with the radialis indicis or the princeps pollicis artery. In 37% of patients, the superficial palmar arch is entirely from the ulnar artery. This superficial palmar arch is the primary source of arterial flow for most of the fingers.

PATHOGENESIS

Hypothenar hammer syndrome is most often due to repetitive blunt force to the hypothenar eminence. Symptoms of ischemia are the result of abnormalities ranging from spasm to thrombosis or aneurysm of the ulnar artery.

Conn suggested the term hypothenar hammer syndrome in 1970, who described repeated blunt trauma of the hand causing ulnar artery damage. Occasionally a single episode of significant trauma can cause hypothenar hammer syndrome. In addition, some patients with hypothenar hammer syndrome may have preexisting fibromuscular dysplasia since angiographic features of fibromuscular dysplasia have been found in the contralateral hand of patients with hypothenar hammer syndrome.

This may explain the disparity between the large number of people at risk for developing hypothenar hammer syndrome and the relatively small number who have the syndrome.

Minor repetitive trauma causes distal vasospasms that can become irreversible, with prolonged injury leading to intimal damage and

hyperplasia.

This gives the artery a classic angiographic corkscrew configuration on an angiograph.

Injury extending to the media leads to progressive fibrosis with ectasia and aneurysm formation. Peri-adventitial tissue involvement leads to extrinsic scarring, vascular narrowing, and thrombosis.

Hypothenar hammer syndrome is a pure vascular injury different from hand-arm vibration syndrome, which is a complex syndrome involving vessels, nerves, muscles, and joints that is due to vibrations from pneumatic or power tools.

Hand vibration and hypothenar syndromes overlap in presentation.

CLINICAL PRESENTATION

Most patients with hypothenar hammer syndrome are middle-aged men in an occupational setting with involvement of the dominant hand.

At risk are workers in any occupation involving repetitive blunt trauma. It may be resulted in baseball players.

The development of hypothenar hammer syndrome is directly proportional to the duration of the trauma, with a mean duration of 21 years. Median patient age at presentation is 42 years.

Pain of the fingers or acute pain over the hypothenar eminence that is exacerbated by repetitive use of the involved hand is characteristic.

Paresthesias, pain, and numbness are due to ulnar nerve irritation or compression. Thumb is spared.

Signs and symptoms due to vascular insufficiency include blanching or discoloration of the finger tips, paresthesias, cold sensitivity, laudication, cyanosis, pallor, and mottling. Chronic cases may present with a

hypothenar mass.

There may be increased capillary refill time, along with a positive Allen test.

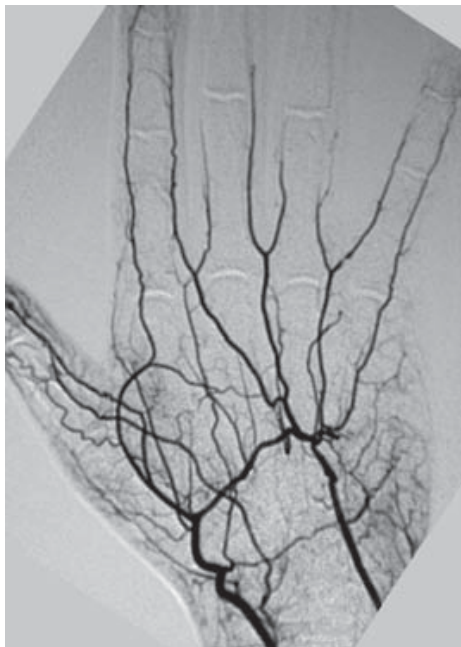
Differential diagnoses

1. Primary Raynaud's disease
2. Clotting or vascular disorders, tobacco or recreational drug use,
3. Vasculitis, diabetic neuropathy, collagen vascular disease,
4. Thromboangitis obliterans, atherosclerosis with secondary thrombosis,
5. Thoracic outlet syndrome.

IMAGING

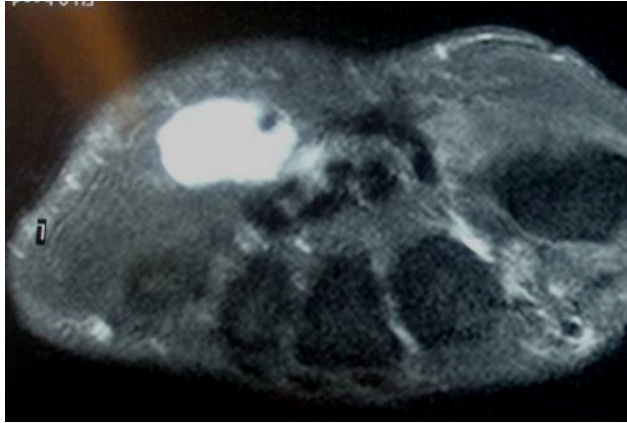
Angiography

1. Delayed filling, occlusion, tortuosity with a typical **corkscrew appearance**, and aneurysm formation of the distal ulnar artery segment.



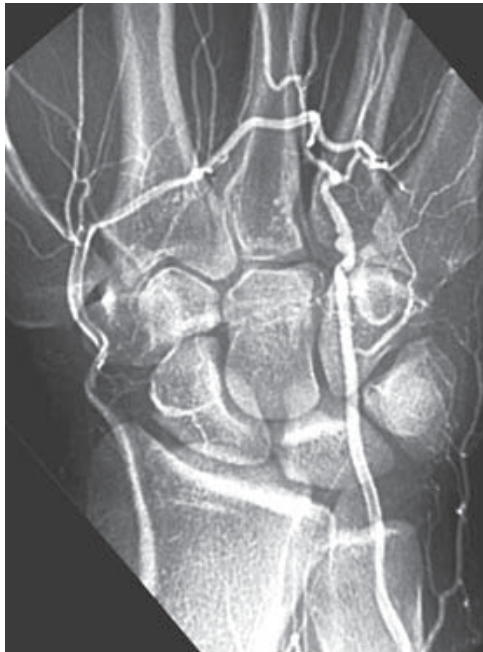2. Magnetic Resonance Imaging

Noninvasive means of assessing the ulnar artery and the swelling: a space occupying in the Guyon's canal.



3. Multi-detector computed tomography (CT) angiography,

Fractures of the hamate and other bony abnormalities causing ulnar artery damage are well shown by multi-detector CT angiography.



4. Ultrasound

Ultrasound is a useful noninvasive diagnostic modality to evaluate the superficial segment of ulnar artery near the hamate with the hook of the hamate acting as a reliable landmark.

TREATMENT

When symptoms are limited to vasospasms and collateral circulation is adequate, non-operative treatment is advocated. This includes low lipid diet, smoking cessation, avoidance of trauma, protective covering of the hand, cold avoidance, calcium channel blockers, antiplatelet agents or anticoagulation, thrombolytics, intra-arterial fibrinolytics.

Cervical sympathectomy has been performed in patients with ischemic ulcers who are poor surgical candidates. Surgical options have included arterial ligation, resection of the diseased arterial segment with end-to-end anastomosis, and resection with vascular reconstruction using a vein or artery graft. Arterial ligation requires an intact radial aspect of the superficial palmar arch.

Direct end-to-end reanastomosis is considered if there is 2 cm of diseased vessel involvement and satisfactory patency of the superficial palmar arch.

CONCLUSION

Hypothenar hammer syndrome is the result of repetitive injury to the hypothenar eminence that is more frequent in men and usually due to job-related work. The syndrome has also been related to sports and recreational activities.

Compressive neuropathies of the ulnar nerve in the canal of Guyon are uncommon compared to ulnar nerve entrapment at the elbow. These entrapments can also result in significant disabilities. Compression can occur in one of three zones. Zone 1 is in the most proximal portion of the canal, where the nerve is a single structure consisting of motor and sensory fascicles. Zones 2 and 3 are distal where the ulnar nerve has divided into motor and sensory branches. The clinical picture correlates with the zone in which compression occurs.

Raynaud's-like symptoms of the fingers are common, but the thumb is not involved. Angiography and MRI are most useful in demonstrating characteristic vascular abnormalities.

Because of variable clinical presentation and paucity of radiological finding, the diagnosis is very often delayed. It has been suggested that a high index of suspicion is required for early proper diagnosis. When the diagnosis is suspected an MRI examination is essential. Although positive nerve conduction or EMG is useful it is not always helpful.

When a space-occupying lesion is demonstrated in the hypothenar eminence majority require surgical excision.

Surgical treatment has been effective, but there is no standard treatment, so the choice of treatment depends on the duration and degree of signs, symptoms, and imaging findings of each patient.

The outcome after surgery is usually favourable.

In summary, we emphasize that the diagnosis of entrapment of the ulnar nerve at the wrist is not easy. Early diagnosis may help in early treatment and hence avoid unnecessary suffering and late complications such as permanent nerve damage.