

ULNOCARPAL IMPACTION SYNDROME

Ulnocarpal impaction syndrome is a degenerative condition with distinct ulnar-sided pathology resulting from abutment of the distal end of the ulna or TFCC against the ulnar carpus.

In an ulnar neutral wrist, the ulnar carpus absorbs 18% of axial load. This increases to 42% when ulnar length is increased 2.5 mm, and decreases to 4.3% when ulnar variance is decreased 2.5 mm.

Increased dorsal tilt of the radius also increases ulnocarpal load. Increasing dorsal tilt from 11° volar to

40° dorsal increases ulnar load from 21% to 65%.

Ulnocarpal impaction syndrome is seen in patients with congenital ulna-positive variance, malunion of the distal radius, Madelung deformity, trauma that affects the growth of the distal radius relative to the ulna, and elbow or forearm trauma such as the radial head injury or Essex-Lopresti injury.

Patients with ulnocarpal impaction syndrome present with insidious onset of ulnar-sided wrist pain. The pain is usually made worse with pronation and ulnar deviation.

The fovea sign is positive in a significant number of patients and the ulnocarpal stress test may reproduce symptoms.

Radiographic findings usually show ulnar-positive variance. If the variance is neutral, a pronated power grip view may show relative lengthening of the ulna up to 2 to 3 mm.

Subchondral sclerosis, subchondral cysts, and “kissing” lesions of the lunate, triquetrum, and ulnar head are characteristic findings. Magnetic resonance imaging findings are distinctive.

Subchondral bone marrow edema is an indirect sign of chondromalacia and is an early finding of ulnocarpal impaction syndrome.

Conservative treatment: Intermittent immobilization, NSAID, and avoidance of ulnar deviation maneuvers may improve symptoms. Corticosteroid injections may serve both therapeutic and diagnostic purposes.

Surgical treatment for ulnocarpal impaction syndrome is based on decompressing the ulnar side of the wrist joint. Ulnar shortening osteotomy and either open or arthroscopic wafer procedure.

The osteotomy is performed at the junction of the distal and proximal third of the ulna.

The standard technique involves a compression plate with either a transverse or oblique osteotomy. With an oblique osteotomy, a lag screw can be used. Specific cutting guides and low-profile plates can be used to make the amount of shortening more precise.

Results of ulnar shortening osteotomy are generally good. Baek reported 29 of 31 good to

excellent results. Fricker reported 89% patient satisfaction.

There are few contraindications to ulnar shortening osteotomy. Absolute contraindications include established DRUJ arthritis and dorsal DRUJ dislocation.

In comparing ulnar shortening osteotomy with the open wafer procedure, Constantine showed similar pain relief and comparable complication rates.

They recommend arthroscopic wafer as their preferred treatment because there is no need for hardware removal and no risk of nonunion.

LT LIGAMENT TEARS

Lunotriquetral ligament tears can be seen in isolation or in combination with other intercarpal or radiocarpal ligament injuries. Initial presentation may include swelling and tenderness over the ulnar side of the wrist. Provocative maneuvers for the LT ligament may be positive. Radiographs may show a VISI pattern. Magnetic resonance arthrography may demonstrate a dye leak at the LT joint.

The primary treatment for isolated, stable LT ligament tears is conservative.

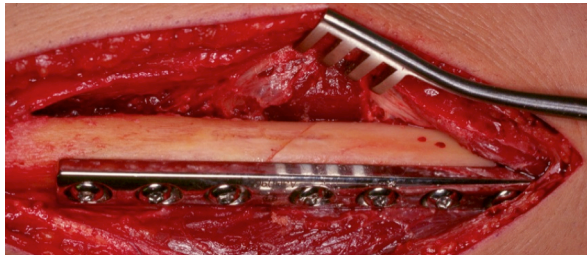
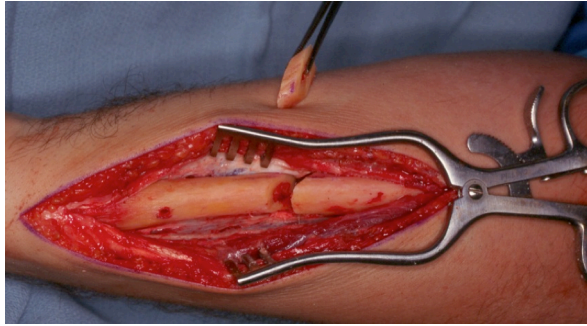
Late treatment for LT ligament tears without instability may involve midcarpal corticosteroid injection. Arthroscopic treatment of LT ligament tears is a reasonable option for injuries that have failed conservative treatment.

Arthroscopic debridement is carried out through the fourth through fifth compartment or ulnar sixth compartment portal. Arthroscopic debridement alone of isolated LT ligament tears may result in symptomatic improvement.

In unstable grade III or IV LT ligament tears, arthroscopic debridement combined with pinning of the LT joint can be considered.

Omokawa described a dorsal capsulodesis using suture anchors, the dorsal radiocarpal ligament, and pinning. Other options for the treatment of LT ligament tears include direct LT ligament tear, LT reconstruction, and LT fusion.

Shin concluded that both objective and subjective results were better in the direct repair and reconstruction groups than the fusion group. Rarely, procedures such as a midcarpal fusion or proximal row carpectomy may be indicated.



References

Sachar. JHS !Vol 37A, July 2012, 1491

2. Shin A comparison of arthrodesis, ligament reconstruction and ligament repair. J Bone Joint Surg 2001;83B:1023–1028.
3. Tatebe: ulnar shortening osteotomy for ulnocarpal impaction syndrome in wrists with neutral or negative ulnar variance. J Hand Surg 2005;30B:129–132.
4. Lichtman. TFCC. I CL 52: 175
5. Barton: Kapandji Procedure: Barton Injury 24:662
6. Results of the modified Sauve Kapandji Procedure in the treatment of Chronic Posttraumatic derangements of DRUJ JBJS 80A: 1758
7. Leslie: Post traumatic conditions and Darrach's: JBJS 75B: 53