

## OSTEOARTHRITIS OF THE WRIST

**Causes:** Osteoarthritis of the wrist may result from

1. Nonunited or malunited fracture of the scaphoid
2. Malunited distal radius;
3. Disruption of the intercarpal DISI leading SLAC
4. Nonunion scaphoid [SNAC]
5. AVN scaphoid and lunate [Kienbocks]
6. Madelung's deformity
7. Primary scaphotrapezium-trapezoid (STT).

### Goal

The surgical treatment of the osteoarthritic wrist rests on basic principles that take into account the location of the arthritis and the most reliable procedure that might eliminate the patient's pain, improve his/her function, and prevent further progression of the pain-generating degenerative process.

### Diagnosis

A meticulous physical examination

ROM

Localization

Instability of carpal and IRUJ

Describe deformity

Radiographic assessment

A key question is whether a planned surgery will cure a patient of his/her chief complaint.

### SLAC

Stage I: Affecting the radial styloid–scaphoid junction

Stage II: Affecting the entire radioscaphoid joint

Stage III: Affecting the entire radioscaphoid joint and the capitulunate articulation

Stage IV: Osteoarthritis affects both the radiocarpal and intercarpal joints

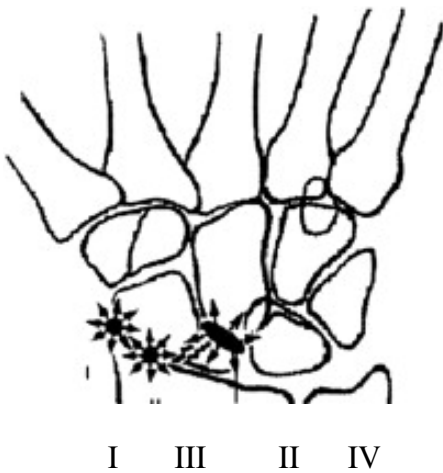
### In SNAC

Stage I: Arthritis localized to the distal scaphoid and radial styloid

Stage II: Radioscaphoid plus scaphocapitate arthritis, but preservation of the lunocapitate joint

Stage III: Arthritis involving radiostyloid, distal scaphoid, scaphocapitate, and lunocapitate.

Stage III: III and radiolunate



The surgical procedures that are performed on the Osteoarthritic wrist depends on:

1. Which joints are preserved and which are destroyed
- 2., a meticulous examination of X ray
3. The head of the capitate, which is the primary articulation for the midcarpal joint, must be evaluated closely.<sup>7</sup>
4. Subtle triquetral or ulnar-sided lunate sclerosis or cyst formation may be signs of ulnocarpal wear.
5. MRI may play a role in the subtle cases of wrist osteoarthritis.

### Treatment

1. Non-operative
  - Splint or cast immobilization,
  - NSAID
  - Cortisone
  - Activity modification

If a patient has debilitating wrist pain referable to an osteoarthritic joint or joints on imaging studies, surgical intervention should be considered.

The goal of performing surgery for such a patient is to eliminate the pain associated with the arthritic joint(s) while trying to preserve as much motion as possible.

**Figure 2.** When examining a posteroanterior radiograph, the primary joints (solid rectangles) to carefully evaluate for degenerative changes are the radioscaphoid, radiolunate, and capitate head. The secondary joints (dotted rectangles) affected include the STT, ulnolunate (with impingement), and radioulnar.

Type of Procedure	% of retained movement
Arthrodesis involving the midcarpal joint	60%
Arthrodesis of radiocarpal without excision of scaphoid	35%
Arthrodesis of radiocarpal with excision of scaphoid	60%
PRC	60%

A total wrist arthroplasty (TWA) may also be possible, although this has been more typically used in patients with rheumatoid arthritis because of the permanent activity restrictions required. If the radiolunate

joint appears to be intact, as in the classic description of a SLAC (or SNAC) wrist, then a scaphoid excision and four-corner arthrodesis may be an appealing option. If the capitate head is preserved, a proximal row carpectomy (PRC) also becomes attractive. If there is isolated ulnocarpal joint or DRUJ pathology, surgically addressing the ulna via shortening or partial or complete resection may be appropriate.

### Surgical Approach

1. Dorsal approach through a vertical incision:

- a. longitudinal incision is used in line with III metacarpal
- b. The third compartment is opened
- c. Allowing a radial transposition of the EPL tendon
- d. Expose Lister's tubercle, which can be removed for harvesting autogenous bone graft.
- e. In the floor of the third compartment and extending distally between the second and fourth compartments, a subcapsular dissection exposing the dorsal carpus.

The EPL tendon is left superficial to the closed retinaculum at the end of the procedure, which avoids adhesions and potential rupture from sharp bone edges at the bone graft site.

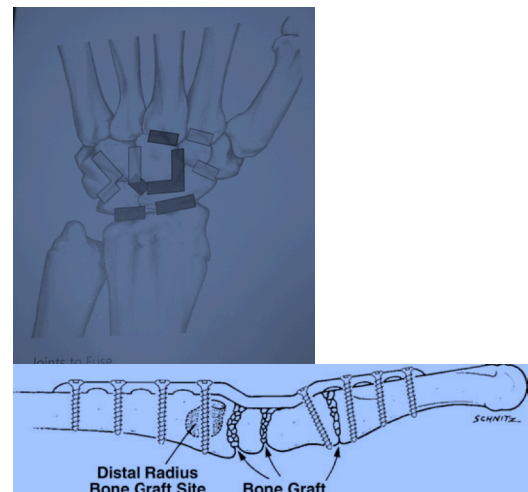
2. Transverse incision

T A common surgical approach to the osteoarthritic wrist, as in scaphoid excision and four-corner arthrodesis or STT fusion.

The advantage of limited transverse incisions is that their appearance after surgery is excellent with little, if any, scar formation. The disadvantage of this incision is that it can be extended only with difficulty, and exposure with protection of the sensory nerve branches can be problematic. If there is any possibility of needing more exposure at the arthrodesis site, alternative incisions are more appropriate. A capsular incision includes a transverse approach (good for limited arthrodeses of smaller magnitude) and a dorsal "T" incision (useful for more extensive limited arthrodeses or proximal row carpectomies).

### Wrist Approach: Basic Principles

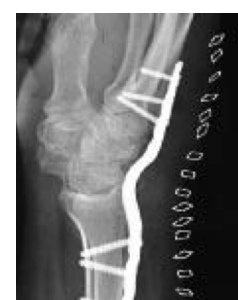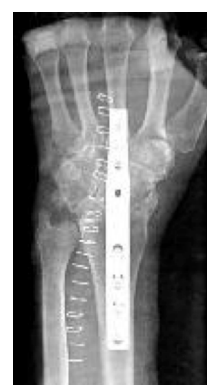1. Keep the capsular incisions precise and maintain the integrity of the capsule as much as possible to allow a careful repair.
2. Preserve the extrinsic and intrinsic ligaments of the wrist that are not affected by the procedure to prevent secondary instability from occurring.
3. In motion-preserving procedures, try to use transverse (or ligament-sparing) capsular incisions
4. Protect sensory branch of the radial and ulnar nerves
5. Excise the posterior interosseous nerve in the floor of the fourth compartment
6. Leave the EPL tendon transposed superficial to extensor retinaculum



### Total Wrist Arthrodesis

<sup>1</sup> Grip is quite strong after this procedure, provided that the arthrodesis is placed in an alignment that allows some extension of the wrist

Generally wrist is fused in the range of 10° to 15° of extension.



The use of autogenous bone graft with a contoured dorsal plate fixation has been shown to produce predictably excellent fusion rates from 93% to 100%.

Not recognizing concomitant DRUJ arthritis or ulnocarpal impaction are potential this procedure.

Advantages:

A high rate of satisfaction and effective pain relief

There was little to no functional disability and good adaptation.

The pain relief parameter was more important than the range of motion parameter.

Total joint fusion cannot completely rescue the early failure of a palliative procedure.

If the wrist injury has a poor prognosis and the functional requirements are high, total joint fusion provides a reliable outcome and very often allows the patient to return to the same job.

### **Total Wrist Arthroplasty**

TWA has become an increasingly attractive surgical alternative in lower-demand individuals who have debilitating osteoarthritis.

Patients who have had a total wrist arthrodesis on one side and a TWA on the other prefer the motion-sparing procedure.

Designed by Swanson, the first total wrist implant was made of silicone and provided good pain relief. Long-term high incidence of implant failure, reactive synovitis and secondary osteolysis have been reported.

Although a new generation of articulated wrists was designed to improve on previous implants and provide an enhanced arc of motion, they suffered from instability problems.

Most data are understandably from patients with rheumatoid arthritis.

TWA has been shown to predictably provide pain relief in most patients while maintaining approximately a 60° arc of wrist motion split evenly between extension and flexion. Lifting of objects should be less than 10 lb (4.5 kg)

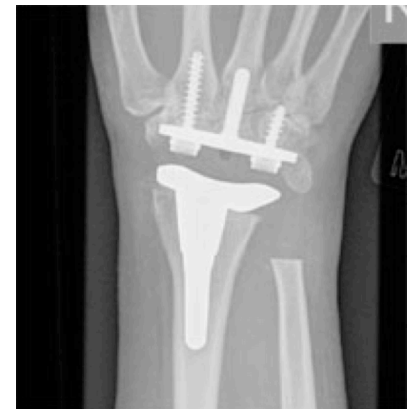Loosening is observed in more than 15% over 10 years and there is a small dislocation rate

### **Distal Ulna**

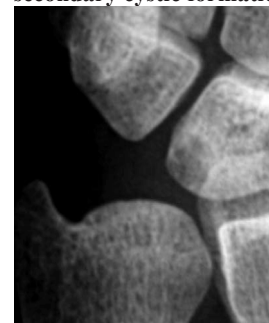
The ulnocarpal articulation bears 20% of the load transferred across the wrist joint.

When ulnar variance increases, which may occur in the setting of shortened distal radius malunions, Palmer and Werner showed that the load transmission across the ulna increases and that abnormal mechanical loading of the ulnocarpal cartilages ensues.

Traumatic insults to the distal radius, ulnar head, or the ligaments of the ulnar wrist may also lead to altered ulnocarpal joint and DRUJ loading and serve as a precursor for osteoarthritis.



ulnocarpal abutment syndrome with secondary cystic formation

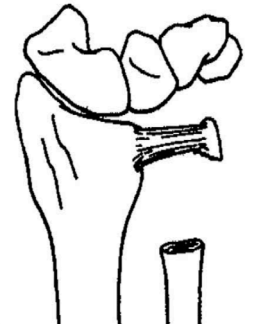

If ulnocarpal arthrosis is thought to be the primary pain generator, surgical treatment should be aimed at performing either a distal radius osteotomy to restore radial height (as in the setting of a distal radius shortened malunion) or shortening the distal ulna to effectively unload what is a diseased, eburnated joint

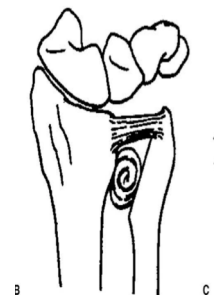Partly as a response to this problem of radioulnar convergence and impingement seen after resecting the distal ulna, endoprosthesis replacement of the ulnar head has attracted a great deal of interest and shows promise.

**Darrach procedure:** Resection of the distal ulnar head

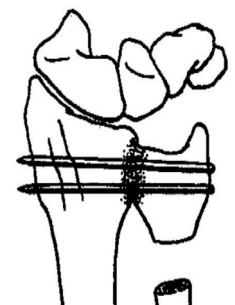
May be performed for osteoarthritis. Care should be taken to make the level of resection proximal to the sigmoid notch of the radius in order to minimize the possibility of post-operative impingement.



**Bower's Procedure:** Hemiresection of the distal ulnar head, with or without tendon interposition, is performed in a patient with good ulnar soft-tissue-stabilizing structures.



**Sauve-Kapandji** may be performed by fusing the DRUJ and resecting a segment of ulnar proximal maintaining the soft-tissue envelope.



**Limited Wrist Arthrodesis**

**Principles**

Take down at least half of the joint surfaces being fused while leaving a small portion of the volar joint intact to preserve carpal spacing.

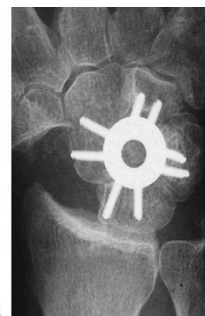Denude osteoarthritic surfaces through the hard subchondral bone to expose cancellous trabeculae to provide more predictable fusion surfaces.

Use high-quality autogenous cancellous graft, usually from the distal radius, and pack it tightly into the spaces exposed at the joints being fused.

Use rigid fixation to allow earlier range-of-motion exercises and to decrease stiffness in the postoperative period.

Check hardware placement with fluoroscopy during surgery to ensure that the hardware does not penetrate into the joints that are not being fused.

Make certain that the carpal bones are in their normal positions before arthrodesis. This is specifically important with the lunate, which is commonly tilted into a dorsal (DISI) or volar intercalated segmental instability (VISI) pattern.



### **Limited wrist arthrodesis: modes of fixation.**

Deciding which definitive method of fixation to use is controversial and highly surgeon dependent.

K-wires have long been regarded as a mainstay in the treatment of hand and wrist arthrodeses. They are inexpensive, easy to use, and provide reliable fixation.

Standard staples either inserted with manual implantation or power implantation provide limited compression but provide good stability between bones. Newer staples that provide a memory compression force may provide more optimal outcomes.

Screws can provide extremely stable compression across an arthrodesis site. Headless screws that are buried beneath the carpal bones offer minimal impingement risk. Getting optimal placement of these types of screws can be problematic because of orientation difficulties.

Dorsal circular plates have been designed to lie recessed fashion on the carpus to minimize impingement.

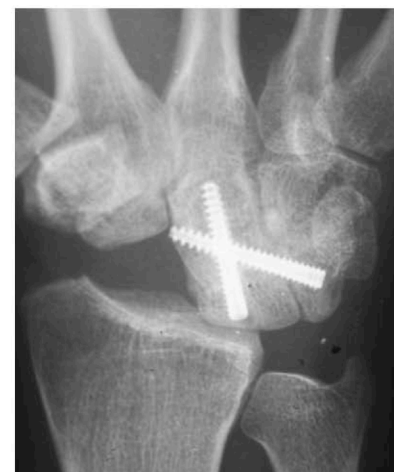### **1. Four corner fusion:** Indicated when lunato-radial joint is intact in SNAC and SLAC.

Scaphoid nonunion advanced collapse wrist is essentially identical in its natural history, although less common. Degenerative changes begin at the articulation between the radial styloid and the distal scaphoid and progress predictably to the entirety of the radioscaphoid joint, followed by the development of midcarpal arthritis. The radiolunate joint is typically preserved.

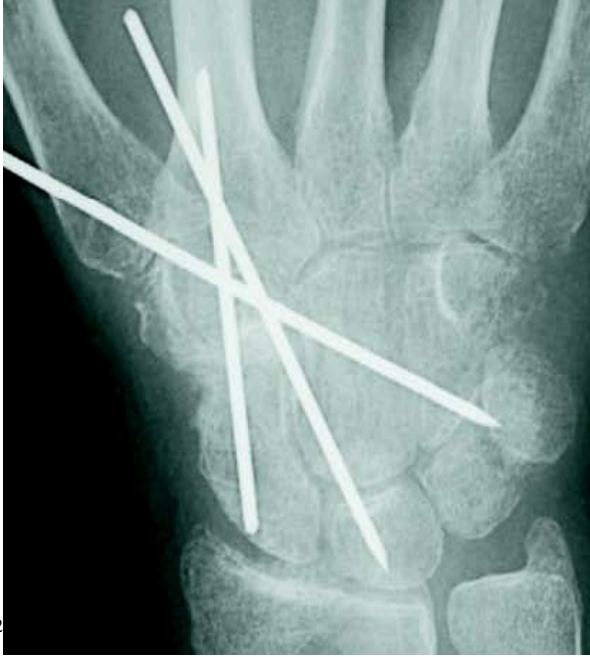Degeneration of the radiolunate joint, as is characteristic of advanced Kienböck's disease, represents a contraindication to four-corner arthrodesis.

The SLAC wrist reconstruction involves complete excision of the scaphoid and arthrodesis of the capitate, lunate, hamate, and triquetrum.

In non-SLAC cases, in which there is isolated midcarpal osteoarthritis and a pristine radioscaphoid joint, a four-corner arthrodesis in situ without scaphoid excision is a viable treatment.



## 2. STT fusion



### STT fusion

The STT joint is a common site of focal arthritis

A limited dorsal transverse incision [3-cm incision] followed by a transverse capsular exposure.

Cartilage denuded, local autogenous bone grafting from the distal radius is harvested.

Internal fixation with K-wires has high union rates and relief of pain.<sup>9</sup>

Also uses in treating rotatory subluxation of the scaphoid.

A radial styloidectomy should always be performed along with this procedure to allow maximum motion after fusion has been accomplished,

About 65% of normal motion after surgery.

**3. Scaphocapitate arthrodesis.** Scaphocapitate arthrodesis is generally used for ligament instability involving the scapholunate joint. For all intents and purposes, this procedure provides the same functional outcome as an STT arthrodesis by maintaining a relatively extended position of the scaphoid, allowing reduction of the scapholunate interval. This procedure is rarely used for osteoarthritis.

It can be used for patients with scapholunate instability and in those rare patients with isolated midcarpal degenerative joint disease who have a good radiocarpal joint.

The scapholunate joint needs to be reduced carefully and completely before arthrodesis.

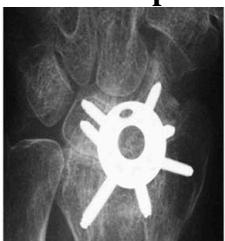It is important to perform a radial styloidectomy with this procedure to prevent impingement during motion.

Internal fixation with K-wires or dorsal plates<sup>75</sup> can be used. 33% to 50% of normal wrist motion after this procedure.

When the cartilage of the capitate head is normal, as in stages I and II SLAC or SNAC wrists, either scaphoid excision and four-corner arthrodesis or PRC represent viable treatment options.

When there is degeneration of the capitate head, however, as in stage III SLAC or SNAC wrists, a PRC is generally contraindicated except in very low-demand patients.

## 4. Radioscapholunate fusion with distal scaphoid excision



## Proximal Row Carpectomy

Proximal row carpectomy is an excellent salvage procedure for the wrist with considerable radiocarpal arthritis provided that the capitate has not had degenerative changes. Proximal row carpectomy is performed through either a transverse or longitudinal incision. The bones of the proximal row are removed on either side of the tendons of the fourth dorsal compartment.

During excision of the proximal row, one must be extremely careful to preserve the integrity of the radioscaphocapitate ligament, which prevents ulnar translation of the capitate off the distal radius. This ligament is especially vulnerable when removing the scaphoid in a piecemeal fashion with an osteotome and mallet.

After removing the scaphoid, lunate, and triquetrum, the distal carpal row migrates proximally so that the head of the capitate articulates with the lunate fossa of the distal radius. Although the arcs of curvature of the capitate and the lunate are not entirely congruent and some point loading occurs during motion, the results of PRC have generally been excellent.

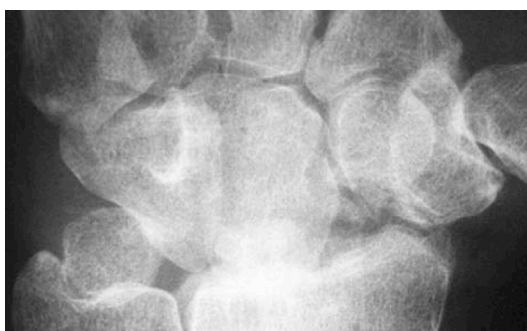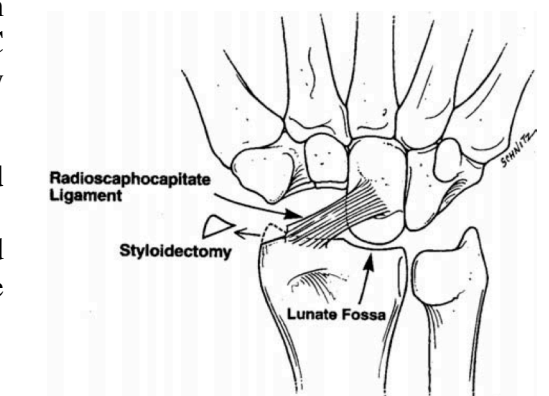
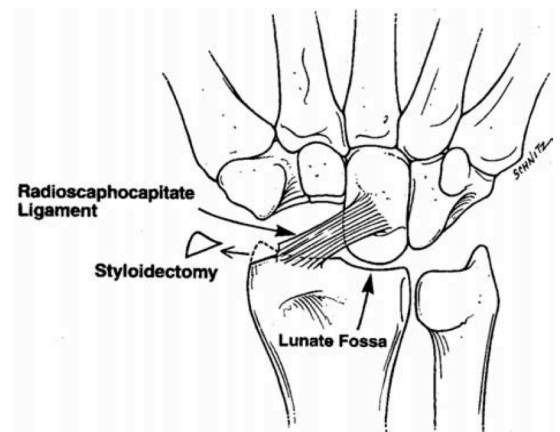
At 10 years, one can conclude that patients having a PRC will achieve over 80% of normal grip strength and 60% of normal motion. Although secondary degenerative changes at the radiocapitate articulation may eventually be seen on plain radiographs, they do not usually preclude a successful clinical outcome.

Comparing patients with post-traumatic wrist arthritis who had a PRC with those who had a total wrist arthrodesis, Smet found no difference in grip strength but less disability in the PRC group. A more frequent comparison in the wrist osteoarthritis literature has been between the 2 most common motion-sparing procedures used today: PRC versus scaphoid excision and four-corner arthrodesis. Thus far, only relatively short-term outcome data are known.

## Proximal Row Carpectomy Versus Scaphoid Excision and Four-Corner Arthrodesis

There are no prospective, randomized trials comparing scaphoid excision and four-corner arthrodesis with PRC as alternative motion-sparing treatments of SLAC or SNAC wrist arthritis.

Advocates of PRC cite its relatively lower technical demands, decreased postoperative immobilization, and—perhaps most of all—its inherent lack of nonunion risk. Proponents of four-corner arthrodesis cite its theoretic advantage of maintaining wrist height; a more physiologic range of motion through a preserved, congruent radiolunate articulation; and lack of eventual degenerative changes in the radiolunate joint.



In all, the study of Cohen supports the notion that there are minimal differences between the short-term clinical outcomes of these 2 procedures.

It would certainly be interesting in the future to determine



the incidence of eventual degenerative changes for each of these procedures to determine if any factors influence the incidence of secondary arthrosis (eg, age or gender of the patient at the time of the initial procedure).

After our discussion of the workhorses of the surgical treatment of wrist osteoarthritis—namely, scaphoid excision, four-corner arthrodesis, and PRC—it is important to recognize 2 other types of carpectomies that may play a role in treating patients with wrist osteoarthritis: pisiform excision and distal scaphoid excision.

Recent study concludes:

1. >35 years: PRC had maintained a satisfactory ROM, grip strength, and pain relief
2. Caution: when used in < 35 years.
3. Presence of degeneration of the radiocapitate joint did not affect clinical result.
4. No longer perform temporary pin fixation.
5. A radial styloidectomy was performed in ten of the twenty-two wrists.

### **Pisiformectomy**

Pisiform excision is the standard surgical treatment for pisotriquetral osteoarthritis. Embedded within the substance of the flexor carpi ulnaris tendon, the pisiform is a sesamoid bone that lies volar to the triquetrum. Pisotriquetral arthrosis is most commonly post-traumatic in nature and has been delineated through cadaveric dissections showing cartilage eburnation on the periphery of the pisiform.

### **Distal Styloidectomy**

Distal scaphoidectomy has been shown in both a cadaveric model and a clinical study to increase flexion and radial deviation after radioscapholunate arthrodeses.

Another possible role for distal scaphoid excision is in the treatment of isolated STT joint osteoarthritis.

Distal scaphoidectomy has also been proposed as an alternative to more extensive procedures in patients who have chronic scaphoid nonunions and resultant distal radioscaphoid or intercarpal osteoarthritis.

Papadonikolakis reported on 13 patients with scaphoid non-unions who were treated with distal scaphoidectomy after prior surgical treatment at a mean follow-up time of 5 years. They showed an increase of mean wrist flexion and extension by 23° and 29°, respectively; a dramatic decrease in pain.

### **Neurectomy:**

Limited neurectomy (Berger technique)

70% of patients have 70% pain relief at 7 years

### **Summary**

Osteoarthritis of the wrist is a commonly encountered condition and has a variety of causes, from idiopathic to traumatic. With a meticulous clinical examination and analysis of radiographs, careful attention paid to the patient's age and functional needs, and adherence to basic surgical principles, successful treatment of the osteoarthritic wrist can be expected.

Despite the successful outcomes that can be achieved in treating patients with wrist osteoarthritis, one should be careful to counsel patients that any of the surgical treatment options presented have positives and negatives, not all of which are evident in the immediate perioperative recovery period. Some procedures are fairly simple and have limited morbidity associated with their use, such as PRC and distal scaphoidectomy; however, their long-term durability is not always ensured. Other more technically involved procedures, such as scaphoid excision and four-corner arthrodesis, may have a higher morbidity and complexity initially, as well as a longer recovery period, but may provide better durability in a younger patient.

## References

1. Proximal Row carpectomy: JAAOS 11: 277
2. Proximal Row Carpectomy JBJS A;86:2359-2365
3. The Journal of Hand Surgery / Vol. 32A No. 5 May–June 2007; 725
4. Orthop & Trauma Volume 97, Issue 4, Supplement, June 2011, Pages S31–S36
5. Radioscapholunate arthrodesis. Hand Clin. 2005 Nov;21(4):561-6.
6. Asymptomatic SLAC. J Hand surgery Vol18, Issue 4, 1993, 682