

# Wooden foreign bodies in the hand

VS Pai, MS Orth, MCh Orth, Orthopaedic Registrar, Memorial Hospital, Hastings.

NZ Med J 1997; 110: 215

Detection of foreign bodies in the soft tissue is a common problem confronting the general practitioner and the emergency physician. Any lacerations, particularly those involving glass fragments, may often result in a retained foreign body. Other common retained foreign bodies include sewing needles, metallic slivers, thorns, splinters and nails.<sup>1-5</sup>

Despite the technical advances in radiological imaging modalities that have occurred in recent years in detecting foreign bodies like wood and plastics, they are not very often relied upon.<sup>2-4,6-8</sup> Five of the six cases reported below seen over a period of 6 months, had a delayed presentation and ultrasound was found to be very useful in detecting and planning the treatment. The author strongly recommends high resolution ultrasound studies (7.5 MHz. linear array transducers) in the surgeon's armamentarium for the detection of retained wooden foreign bodies.

## The patients

The following six cases presented to the emergency department of Memorial Hospital, Hastings between December 1995 and May 1996. All patients underwent real time, high resolution ultrasound studies (7.5 MHz, linear array transducers) to rule out the presence of a wooden foreign body in their hands.

**Patient 1:** A 50 year old man had a negative exploration of the right hand under local anaesthesia elsewhere for wooden splinter. Two weeks later he presented to us with pain and swelling and ultrasound revealed two linear echogenic foci in different planes within the soft tissue (Figure 1), consistent with two wooden fragments found at surgery. He was treated with antibiotics as there was infection at the time of exploration.

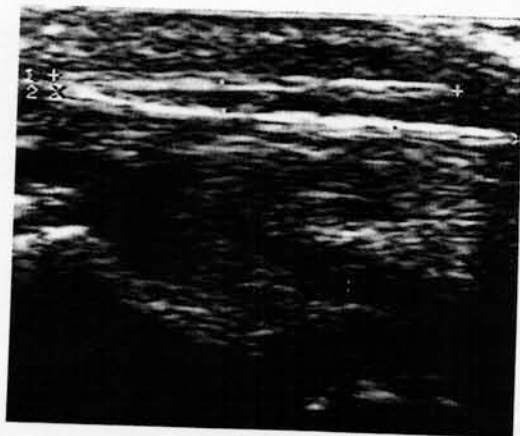


Figure 1. — Ultrasonogram demonstrating the retained two pieces of wooden foreign bodies in the soft tissue over the thenar muscles.

**Patient 2:** An 18 year old man injured his right thenar area with a bamboo stick, which he partly removed on the same day. Two days later he presented with infection and was started on antibiotics by his general practitioner as x-ray examination did not reveal any foreign body. A week later, he was referred for persisting discharge and an ultrasonogram demonstrated an echogenic focus and a wooden fragment was found at surgery.

**Patient 3:** A 39 year old gardener had thorn injury to his first right web space and he presented two weeks later with indurated swelling over the base of the index finger and irritation of the radial digital nerve of the index finger. Ultrasound examination revealed a foreign body. With removal of the thorn and a course of antibiotics he became symptom free.

**Patient 4:** 27 year old man fell, striking a piece of wood with his left hand. He attempted to pull out the foreign body but felt something left inside. This was explored elsewhere under local anaesthesia without much success. He had reexploration following an ultrasound examination and a 1.5 cm wooden fragment was removed.

**Patient 5:** A 4 year old girl had a wooden splinter injury to the base of left thumb while playing at school. This was initially explored by her doctor and but no foreign body was found. A week later she was referred for pain and swelling. Ultrasound revealed a 2 cm echogenic focus surrounded by fluid in the soft tissue. At surgery, a foreign body with pus was removed and she was given a course of antibiotics.

**Patient 6:** A 64 year old man presented with injury to his right thenar region with a wooden splinter while at work. His general practitioner tried to remove it under local anaesthesia. Although the foreign body was felt, he was unable to remove it and therefore referred the patient to the emergency department without delay. Ultrasound revealed a 4.5 cm linear echogenic focus which was partly broken and bent. This was explored under local anaesthesia and a tourniquet and the foreign body was fully retrieved.

## Discussion

Nonmetallic foreign bodies may be missed on initial examination, both clinically and radiologically. Anderson<sup>1</sup> reviewed 200 cases of retained foreign bodies and found that one third of the cases had been missed by the previous treating surgeons. Missed or retained foreign bodies can cause abscess, discharging sinus, osteomyelitis, tenosynovitis, monoarticular arthritis and sterile inflammatory reaction.<sup>1,5,9</sup> Accurate diagnosis and localisation of retained foreign bodies is therefore essential. While most metal and glass foreign bodies are detectable on radiographs, wood and plastic are not seen on x-rays and they can be easily missed. When suspicion of a wooden or plastic foreign body is high, other imaging methods such as ultrasound, CT or MRI should be considered.<sup>2,5-8</sup>

The cases reported here illustrate how easy it is to miss these foreign bodies even after an exploration in the general practitioner's surgery or doctor in the emergency department. Ideally all nonmetallic foreign bodies should be subjected to ultrasound examination, but this procedure is highly recommended when exploration is negative or if the wound fails to heal. Advantage of ultrasound is not only in localising the nonmetallic foreign body in the soft tissue, it also gives exact size, shape and number of foreign bodies.

**Acknowledgements.** I would like to thank Dr Ship, radiologist, and Dr. Peter Lloyd for their help in preparing this manuscript. I am also grateful to Mr Wayne Blair, medical photographer, Memorial Hospital for his help.

**Correspondence.** Dr VS Pai, Memorial Hospital, Hastings.

- Anderson M, Newmeyer WL, Kilgore ES. Diagnosis and treatment of retained foreign bodies in the hand. *Am J Surg* 1982; 144: 63-5.
- Bodine D, Quinn S, Cochran C. Imaging foreign glass and wooden bodies of the extremities with CT and MRI scanning. *J Comput Assis Tomog* 1988; 12: 608.
- De Flaviis L, Scaglione P, Del Bo P, Nessi R. Detection of foreign bodies in soft tissues: experimental comparison of ultrasonography and xeroradiography. *J Trauma* 1988; 28: 400-4.
- De Lacey G, Evans R, Sandin B. Penetrating injuries: how easy is it to see glass and plastics on radiographs? *Br J Radiol* 1985; 58: 27.
- Flom LL, Ellis GL. Radiologic evaluation of foreign bodies. *Em Med Clin North Am* 1992; 10: 163-77.
- Gooding GAW, Hardiman T, Sumers M, et al. Sonography of the hand and foot in foreign body detection. *J Ultrasound Med* 1987; 6: 441-7.
- Hansson G, Beebe AC, Carroll NC, Donaldson JS. A piece of wood in the hand diagnosed by ultrasonography. *Acta Orthop Scand* 1988; 59: 459-60.
- Little CM, Parker MG, Callowich MC, Sartori JC. The ultrasonic detection of soft tissue foreign bodies. *Invest Radiol* 1986; 21: 275-7.
- Siegel IM. Identification of non-metallic foreign bodies in soft tissue: *Eikenella corrodens* metatarsal osteomyelitis due to a retained toothpick. *J Bone Joint Surg* 1992; 74 (Am): 1408-10.