

Management of unreduced traumatic posterior dislocation of the hip: heavy traction and abduction method

V. S. Pai and B. Kumar

Kasturba Medical College, Manipal, India

Eight cases of unreduced traumatic posterior dislocation of the hip were treated by heavy traction and abduction. In four out of eight cases a concentric reduction was obtained. In two patients where a concentric reduction was not obtained, open reduction was performed. In these patients, there was an excellent or good result. In the remaining two patients a non-concentric reduction was accepted, and they had poor clinical results.

Introduction

Reduction of an old dislocation of the hip is not only difficult but results in an increased risk of avascular necrosis and arthritis (Brav, 1962; Funk, 1962; Epstein, 1973; Garret et al., 1979). However, Buchanan (1962), Nixon (1976) and Varma (1975) treated hips which had remained dislocated for periods of up to 1 year by operative reduction and had reasonably good results. Alternatives to reduction are subtrochanteric osteotomy, excision arthroplasty, replacement arthroplasty, and arthrodesis.

The literature is unclear on the definition of 'late' or 'old' or 'neglected' dislocation of the hip. Garret et al. (1979) suggested that patients who were not treated within 72 h of injury were considered to have an old dislocation.

We report eight patients with old dislocation of the hip treated by the heavy traction and abduction method. A similar study was carried out by Gupta and Shrivast (1977), who reported good results in seven out of their eight cases.

Materials and methods

The material consists of eight old unreduced posterior dislocations of the hip seen in the orthopaedic department of Kasturba Medical College, India between 1981 and 1984. The mechanism of injury was a fall while playing in three, a blow on the back in two, a fall from a tree in one and a vehicular accident in two cases. All these patients were initially treated elsewhere and then referred to our centre for more than one of these findings: pain, limp, shortening and deformity (Table I). The mean age was 11.6 years (range 3-30 years).

Table I. Summary of eight patients

No.	Sex/age	Type*	Neglect period†	Injury	Treatment	Follow-up	Results
1	M/3	I	Group III	Fall from bed	H. T. - abduction‡	3 years	Excellent
2	F/4	I	Group III	Fall at play	H. T. - abduction	5 years	Excellent
3	M/5	I	Group II	Fall at play	H. T. - abduction	3 years	Excellent
4	F/30	I	Group II	Dashboard injury§	H. T. - abduction	2 years	Excellent
5	F/3	I	Group II	Struck by object	H. T. - abduction Open reduction§	4 years	Good
6	M/25	I	Group III	Fall from tree	H. T. - abduction Open reduction§	4 years	Good
7	M/11	III	Group II	Roof collapse§	H. T. - abduction Refused surgery	4 years	Poor (arthritis)
8	M/12	III	Group IV	Bicycle accident	H. T. - abduction Adductor tenotomy§ Refused Surgery	3 years	Poor (redislocation)

* Stewart and Milford classification: Grade I - Simple posterior dislocation
 II - Dislocation with fracture rim of acetabulum
 III - Dislocation with major acetabular fracture
 IV - Dislocation with femoral head/neck fracture

† Neglect period: Group I - 3 days to 3 weeks; Group II - 3 weeks to 3 months
 Group III - 3 months to 1 year; Group IV - More than 1 year

‡ H. T. - Abduction: Heavy traction and abduction method.

§ Associated injuries: Case 4: There was an ipsilateral fracture of femur.
 Case 5: Associated head injury, pelvic fracture with urethral tear.

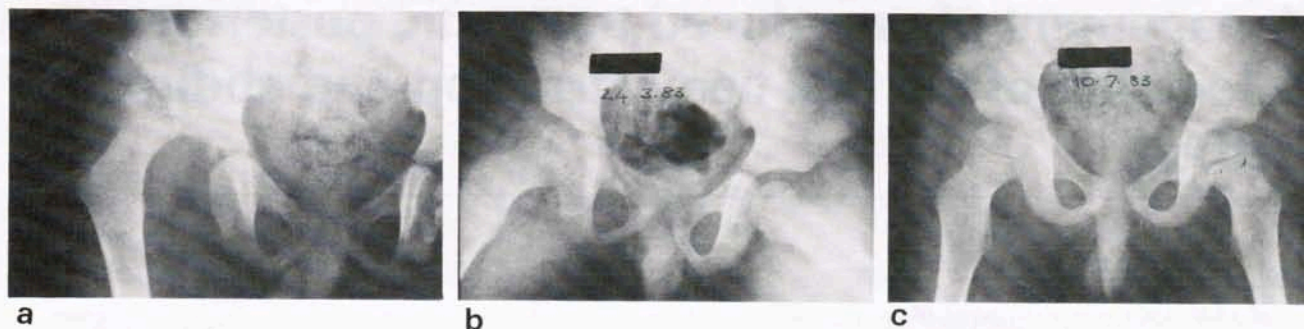

Figure 1. Six-month-old posterior dislocation of right hip in a 6-year-old child. *a*, Before reduction. *b*, Result 3 weeks after heavy traction and abduction. *c*, Six months after reduction. Four years after reduction, the range of motion of the hip joint was normal.

Skeletal traction was applied through the lower femur or upper tibia, for a period of 2 to 3 weeks. With a traction of 4.5–13.6 kg (10–13 lb), over-reduction was achieved in all eight cases. Gradual reduction of the femoral head into the acetabulum was then accomplished by abducting the limb and reducing the traction to 2.3–3.2 kg (5–7 lb) for 3 weeks.

Traction was followed by non-weight bearing hip mobilization for 6 weeks in adults. In children, the joint was immobilized in a hip spica for 6 weeks.

In one patient (*Case 8*), adductor tenotomy was performed prior to traction.

The mean follow-up period was 3.5 years (range 2–5 years).

Results

The results were graded as Excellent, Good, Fair and Poor according to criteria used by Epstein (1974) (*Table II*).

Excellent: Full range of movement, no pain, no radiological changes.

Good: No pain; no more than a slight limp; 75 per cent of normal range of movement. Minimal radiographic changes.

Fair: Pain, but not disabling; moderate limp; limited hip movement; radiological changes of avascular necrosis and traumatic arthritis.

Poor: Disabling pain; stiff hip; re-dislocation; bad limp; radiographic complete loss of joint space; deformed head redislocation.

Concentric reduction was achieved in four patients with excellent clinical results (*Figure 1*).

In four patients after reduction by this method, the radiograph revealed an increased medial joint space. In two of these, open reduction was carried out through a posterolateral approach (*Figure 2*). Buttonholing of the capsule was found to be the cause for non-concentric reduction. Reduction was maintained by transarticular Kirschner wires and a hip spica cast. The result was graded good in these two cases.

In *Case 7* and *Case 8*, non-concentric reduction was

Table II. Results of heavy traction and abduction

Reduction	Excellent	Good	Fair	Poor
Concentric	4	—	—	—
Nonconcentric				
<i>a.</i> Followed by open reduction	—	2	—	—
<i>b.</i> Position accepted	—	—	—	2

accepted as patients refused operative reduction. Post-traumatic arthritis in one patient and redislocation (*Figure 2*) in the other patient were responsible for poor results in these patients.

Discussion

Neglected traumatic dislocation of the hip is not uncommon in developing countries. Unlike adults, in children trauma sustained may be relatively slight and a trivial fall may account for the dislocation (Funk, 1962).

It has been well documented that delayed reduction increases the risk of avascular necrosis and post-traumatic

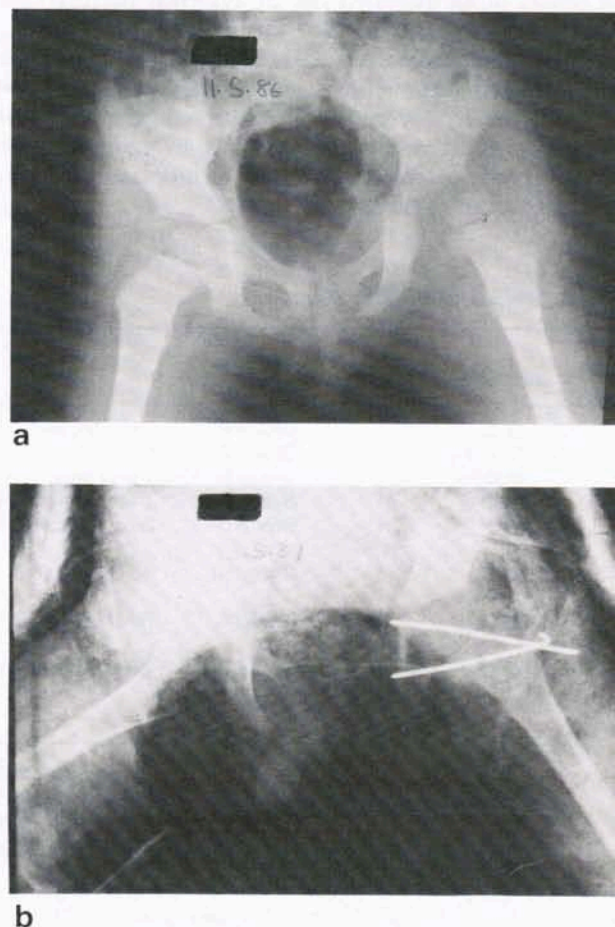


Figure 2. This 3-year-old patient was treated for posterior dislocation of the right hip by heavy traction. *a*, Radiograph 3 weeks later shows increased medial joint space. *b*, The hip was reduced through a posterolateral approach and stabilized with transarticular Kirschner wires and a hip spica cast.

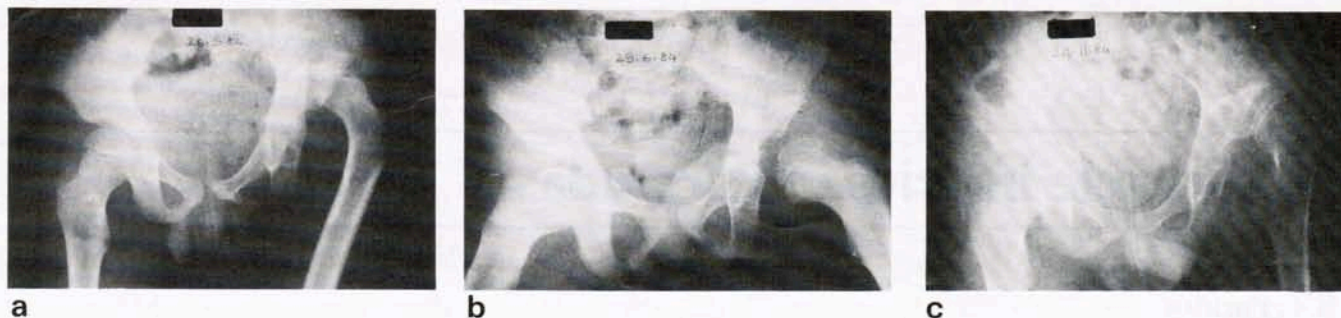

Figure 3. An 18-month-old neglected posterior dislocation of hip initially treated by massage. *a*, Fracture-dislocation left hip. *b*, Non-concentric reduction after 3 weeks of heavy traction. Patient refused surgical reduction. *c*, After 6 months he presented with redislocation and had poor clinical results.

arthritis (Stewart and Milford, 1954; Brav, 1962; Epstein, 1973). It is generally conceded that the end result following posterior dislocation is dependent on the age of the patient, type of dislocation and severity of initial trauma (Funk, 1962; Epstein, 1973).

The incidence of avascular necrosis varies from 6 per cent to over 40 per cent in Western literature (Stewart and Milford, 1954). Brav (1962) reviewed 262 dislocations and found a relationship between the time of reduction and the incidence of avascular necrosis. He observed that when reduction was achieved by manipulation or open reduction, the incidence of avascular necrosis in dislocations which were reduced after 12 h was three times that in those which were reduced within 12 h. In contrast, Gupta and Shrivat (1977), Nixon (1976) and Varma (1975) showed that delay did not jeopardize the end result. Our study lends strong support to this observation. We feel that the absence of avascular necrosis in our series was probably due to gradual stretching of the soft tissue around the hip. Gupta and Shrivat (1977) have suggested that the pressure exerted on the articular cartilage of the acetabulum and femoral head is the determining factor in avascular necrosis.

In our opinion, the failure of the soft tissue to stretch out, thereby causing increased pressure on the articular cartilage, is an important factor in the development of avascular necrosis.

Brav (1962) related the incidence of avascular necrosis to the degree of initial trauma. The trauma sustained by most of our patients was relatively slight. This may have contributed to the absence of avascular necrosis in our series.

All patients had follow-up exceeding 2 years. Stewart (1971) reported that avascular necrosis does not supervene after 2 years if it has not already become manifest.

The literature is replete with reports of unsatisfactory results following reduction in fracture dislocation of the hip (Grade III). We failed to achieve concentric reduction in the two Grade III fracture-dislocations treated by the traction method, with subsequent poor results.

It is now our policy to utilize the heavy traction-abduction method to treat all cases of old posterior dislocations (Stewart-Milford Grade I and II) where the period of neglect is less than 1 year. The goal of treatment is to achieve a concentric reduction. Any widening of the medial joint space should indicate interposition of soft tissue or bony fragments. Operative reduction is mandatory in these cases to achieve optimal results (*Case 5* and *Case 6*).

Conclusion

Our study indicated the following:

1. When instituted within 1 year of injury, the heavy

traction and abduction method is a useful method in reducing an old posterior dislocation of the hip.

2. In about two-thirds of isolated posterior dislocations, concentric reduction can be achieved by this method.
3. When concentric reduction is not obtained by this method, operative reduction is mandatory for optimal results.
4. The prognosis is poor when dislocation is complicated by a fracture of the acetabulum (Stewart-Milford Grade III).
5. None of the patients developed avascular necrosis.
6. Pessimism about the prognosis of an old dislocation is not justified.

References

- Brav E. S. (1962) Traumatic dislocation of the hip. Army experience and results over a twelve year period, *J. Bone Joint Surg.* **44A**, 1115.
- Buchanan J. J. (1962) Open reduction of old dislocation of the hip. *Surg. Gynecol. Obstet.* **31**, 462.
- Epstein H. C. (1973) Traumatic dislocation of the hip. *Clin. Orthop.* **92**, 116.
- Epstein H. C. (1974) Posterior fracture dislocations of the hip, long-term follow-up, *J. Bone Joint Surg.* **56A**, 1103.
- Funk F. J. (1962) Traumatic dislocation of the hip in children *J. Bone Joint Surg.* **44A**, 1135.
- Garret J. C., Epstein H. C., Harris W. H. et al. (1979) Treatment of unreduced traumatic posterior dislocations of the hip, *J. Bone Joint Surg.* **61A**, 2.
- Gupta R. C. and Shrivat B. P. (1977) Traumatic dislocations of hip. *J. Bone Joint Surg.* **59A**, 249.
- Nixon J. R. (1976) Open reduction of traumatic dislocation of the hip. Report of three cases. *J. Bone Joint Surg.* **58B**, 41.
- Stewart, Marcus (1971) Dislocations. In: *Campbell's Operative Orthopaedics*, 5th Ed., Vol. 1. A. H. Crenshaw (ed.). St Louis: C. V. Mosby, 422.
- Stewart M. J. and Milford L. W. (1954) Fracture-dislocation of the hip. An end result study. *J. Bone Joint Surg.* **36A**, 315.
- Varma B. P. (1975) Management of old unreduced traumatic dislocations of the hip. *Indian J. Orthop.* **9**, 69.

Paper accepted 20 November 1989.

Requests for reprints should be addressed to: Dr V. S. Pai, Flat B-39, Arrowe Park Hospital, Arrowe Park Road, Upton, Wirral, Merseyside L49 5PE, UK.