

Journal of Orthopaedic Surgery 1998, 6(1): 79-81

Pozo's procedure for dislocating peroneal tendons following a calcaneal fracture: A case report

VS Pai

Hastings Memorial Hospital, Hastings, New Zealand.

INTRODUCTION

The sequelae of displaced os calcis fractures have been a significant problem and their management continues to remain a controversial issue. Various techniques of lateral decompression of the calcaneum have been reported.^{2,4} In this report, the author describes a case of a malunited os calcis fracture with recurrent subluxation of the peronei tendons which was treated by lateral calcaneal osteotomy and rerouting these tendons deep to the calcaneofibular ligament (Pozo's procedure³).

Key words: *dislocating peroneal tendons, calcaneal fracture, Pozo's procedure, calcaneofibular ligament*

CASE REPORT

A 22-year-old man was admitted, via the emergency room, after a fall of 4 m onto hard ground. He complained of a painful left foot. Examination revealed a swollen, tender hindfoot with no surface wounds. Plain radiographs demonstrated a comminuted fracture of the os calcis with extension into the subtalar joint. Bohler's angle was preserved.

He was initially treated with rest, elevation, ice,

analgesics and physiotherapy. His recovery was uncomplicated and the foot was fully weight-bearing at the end of 3 months. Six months later, in the follow-up clinic, he presented with a history of a painful snapping sensation over the lateral aspect of the right ankle while at work as well as when jogging. On examination there was mild broadening of the calcaneum. There were visible dislocating peroneal tendons on forceful dorsiflexion and eversion of the ankle onto the lateral aspect of the malleolus. As this was causing him significant discomfort, he was offered a surgical stabilisation procedure for subluxating peroneal tendons.

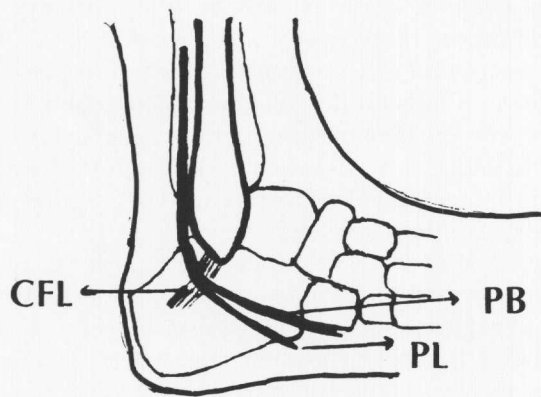
A modified Kocher approach to the calcaneus was performed under pneumatic tourniquet. At the time of exploration it was noted that the peronei were displaced by the protruding lateral wall of the os calcis. Decompression of the tendons was carried out by lateral calcaneal osteotomy,² taking care not to damage the attachment of the calcaneocunieform ligament, and the tendons were rerouted deep to the calcaneofibular ligament by osteotomizing the lateral malleolus, as suggested by Pozo³ (Figs. 1,2). The ankle was immobilised in a short leg nonwalking cast for the first 3 weeks, followed by a weight-bearing cast for another 3 weeks.

Postoperative evaluation demonstrated a good early clinical result, including peroneal tendon function. At 9-month follow-up he had returned to his normal work. He had minimal pain. Subtalar

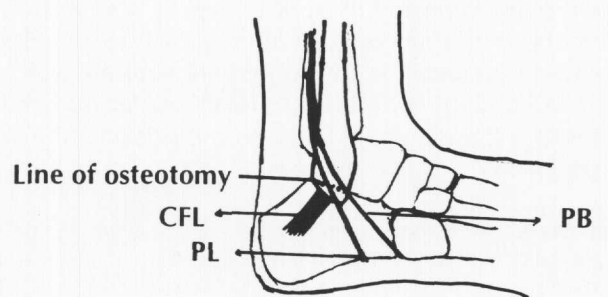
Address correspondence and reprint requests to: Dr VS Pai, Hastings Memorial Hospital, Hastings, New Zealand.

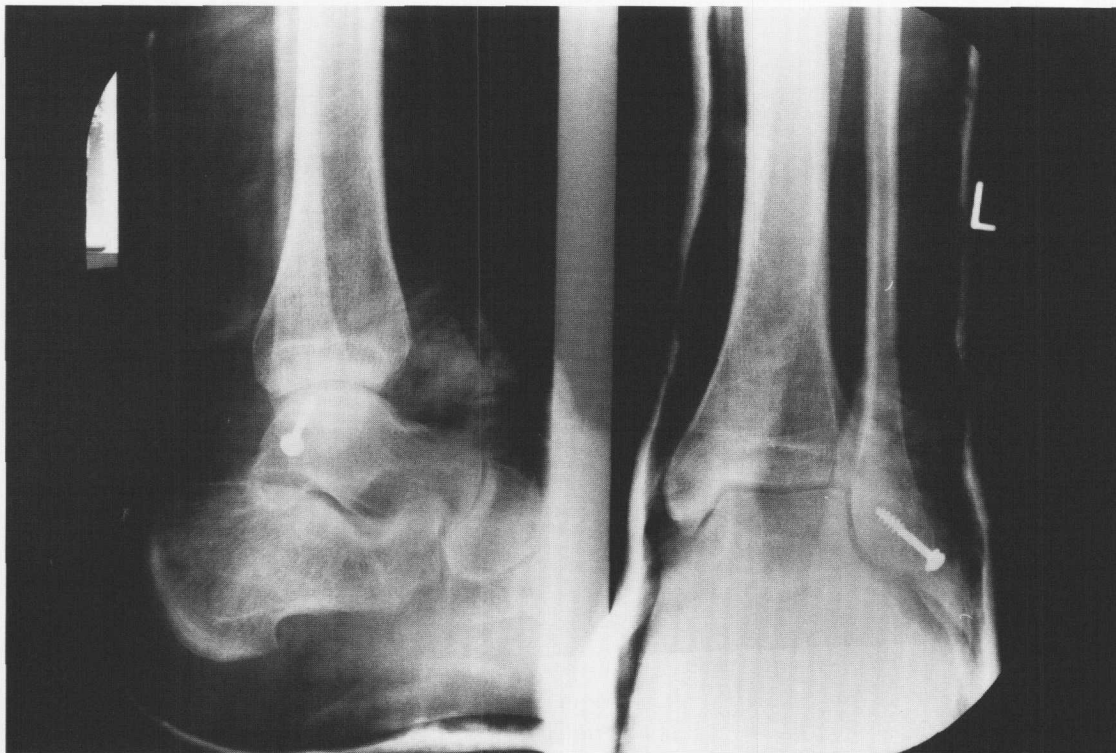

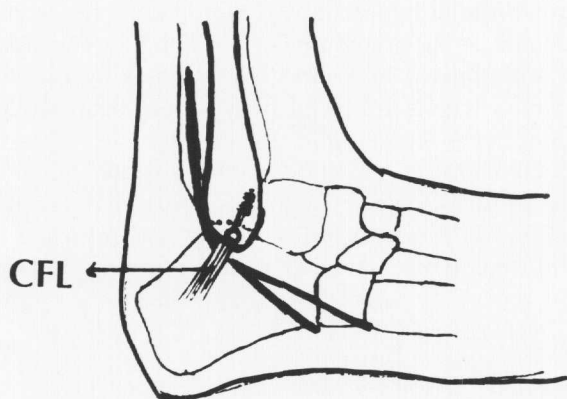
Figure 1 X-ray showing fixation of fibular osteotomy (Pozo's procedure).



(a)



(b)



(c)

Figure 2 (a) Peroneal tendons in a normal position, superficial to the calcaneofibular ligament (CFL). (b) Peroneal tendons in dislocated position. (c) Rerouted peroneal tendons with the osteotomized fragment fixed with a screw. PB: Peroneus brevis. PL: Peroneus longus

motion was restricted to 50% of normal and the peroneal tendons were functioning well.

DISCUSSION

Dislocation of the peroneal tendons is an uncommon condition. Alm et al.¹ reported 10 cases secondary to competitive sports injury which appeared to be either the result of a direct blow on the posterior aspect of the lateral malleolus or forceful supination and plantar flexion of the foot. None of his patients had a fractured calcaneum.

Peroneal tenosynovitis is a well recognised cause of persistent pain following a calcaneal fracture.⁶ Recently, Rosenberg et al.⁵ reviewed 24 consecutive intraarticular calcaneal fractures and reported a 92% incidence of peroneal tendon abnormalities on CT examination. Abnormal findings included lateral displacement (58%), impingement (33%), subluxation or dislocation (25%) and haematoma (21%). At 10 months following injury, only 5 had evidence of tenosynovitis and one had painless snapping of the peroneal tendon. None of the patients in this series had a stabilisation procedure for a subluxating peroneal tendon.

Traditionally, the pain and disability associated with calcaneal fractures has been attributed to traumatic arthritis. Braly et al.² however did not share this view and felt that impingement of the calcaneum on the lateral malleolus, with resultant peroneal tendon displacement and tenosynovitis, as well as sural nerve entrapment or neuroma formation, are potential sources of pain. They recommended lateral calcaneal osteotomy, sural nerve release with or

without lengthening of the peronei tendons, and reconstruction of the retinaculum.

The peronei tendons descend posterior to the lateral malleolus and proceed obliquely across the lateral calcaneal wall towards their insertion site. The peroneus longus and brevis tendons are in intimate contact with the calcaneus between the superior and inferior peroneal retinacula, and are separated only by their synovial sheaths.

The proposed sequence of events in this reported case is as follows: (1) A burst fracture of the calcaneum and consequent broadening of the heel, (2) the peroneal tendon pushed more laterally, (3) weakening or stretching of the superior peroneal retinaculum, (4) subluxation of the peroneal tendons from the fibular groove. Subluxation of the tendons caused significant disability in this patient and he responded well to the rerouting procedure. The author feels that the procedure of rerouting peroneal tendons is ideal in the case of a malunited os calcis. Osteotomising fibula with the calcaneofibular ligament provides more exposure of the lateral wall of the calcaneum and hence complete decompression of the calcaneum can be carried out.

ACKNOWLEDGEMENTS

The author is grateful to Dr Peter Lloyd for his help in preparing this manuscript and Mr Wayne Blair, medical photographer, Memorial Hospital. No benefits in any form have been received or will be received from a commercial party related directly or indirectly to the subject of this article.

REFERENCES

1. Alm A, Lamke LO, Liljedahl SO. Surgical treatment of dislocations of peroneal tendons. *Injury* 1975, 7:14-7.
2. Braly WG, Bishop JO, Tullos HS. Lateral decompression for malunited os calcis fractures. *Foot & Ankle* 1987, 6:90-6.
3. Pozo JL, Jackson AM. A rerouting operation for dislocation of peroneal tendons: Operative technique and case report. *Foot & Ankle* 1984, 5:42-5.
4. Rockwood CA, Green DP, Bucholz RW, Heckman JD. *Rockwood and Greens Fractures in Adults*, Vol.2, 4th ed. Philadelphia:Lippincott-Raven 1996, 2352.
5. Rosenberg ZS, Feldman FF, Singson RD, Price GJ. Peroneal tendon injury associated with calcaneal fracture: CT findings. *Am J Radiol* 1987, 149:125-9.
6. Slatis P, Kiviluoto O, Santavirta S, Laasonen EM. Fractures of the calcaneum. *J Trauma* 1979, 19:939-43.