

A Massive Foot Ganglion: Case Report

by Vasu Pai MS, D (Orth), National board (Orth), FICMR, FRACS, MCh (Orth) ¹ ✉, Vishal Pai, M.B., Chb²

Podiatry Internet Journal 3 (1): 2

Ganglion is one of the most common benign soft tissue swellings. The most common location is dorsum of the hand. However, it is not uncommon in the foot, but a massive ganglion is very rare. The case presented is one of a large, expanding ganglion over the dorsal aspect of the foot. This was successfully removed surgically.

Key words: Foot, Ganglion, benign tumor

Published online: January 1, 2008

The foot is a relatively uncommon site of neoplastic and non-neoplastic soft tissue tumors. Although it contains a relatively small amount of somatic soft tissue elements, the foot is considerably rich in tendons, fasciae, retinaculae, and synovium. Corresponding to this distribution of soft tissue elements, some soft tissue lesions, such as ganglion, giant cell tumor of tendon sheath, fibromatosis, and synovial sarcoma, are commonly seen in this location.

Ganglia, caused by mucinous transformation of periarticular connective tissue, are the most common cystic lesions found around the joints or tendon sheath. Common locations of ganglion are the hand, foot, and knee. Ganglion may be single or multi loculated and can be subcutaneous or deep or sometimes intraosseous. We report here a massive multiloculated subcutaneous ganglion of the foot arising from the extensor tendon sheath of the foot.

Case Report

A 36-year-old woman presented with a rapidly increasing, large, painless, soft swelling involving the dorsum of her right foot. The lesion engulfed the whole of the dorsal aspect of the foot with more swelling over the lateral side. (Fig. 1,2) The swelling appeared lobulated and was approximately 14 cm x 8 cm. The lesion was subcutaneous, and the overlying skin was stretched considerably. The swelling was cystic and translucent. There was no history of trauma.

Because of the large size of the lesion, the patient had considerable difficulty wearing her normal footwear. The patient also noticed that the swelling fluctuated on and off. There was no vascular or neurological compromise of the toe.

Blood tests were normal. X-ray was unremarkable and did not reveal any bony erosion adjacent to the swelling. An ultrasound examination revealed a pure cystic lesion. As swelling appeared benign and cystic, MRI was not performed.

Address correspondence to: Dr. Vasu Pai, Gisborne Hospital, Ormand Road, Gisborne, New Zealand.
E-mail: vasuchitra@gmail.com

¹ Orthopaedic Specialist, Gisborne, Hospital, Ormand Road, Gisborne, New Zealand.

² House Surgeon, Middlemore Hospital, Auckland, New Zealand.

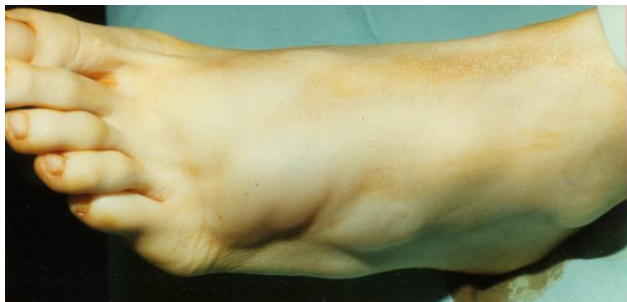

Figure 1 Massive left foot ganglion cyst.

Surgical excision was performed. The mass separated from the surrounding skin quite easily. It appeared to be arising from the extensor tendon of the foot. (Fig. 3) There was a well-defined capsule. The fluid of swelling is gelatinous and is typical of ganglion fluid. Histological examination showed a benign ganglion. At 2 year's follow-up, there was no recurrence. The patient was able to wear his proper footwear.

Discussion

Approximately 75% of all biopsy-proved soft-tissue masses of the foot and ankle are benign tumors.¹ In some cases, it may be difficult if not impossible to identify the lesion; however, careful analysis of the magnetic resonance (MR) imaging findings and correlation of these findings with the patient's clinical history can usually suggest a more specific diagnosis, particularly in the most common benign tumors of the foot such as fibromatosis, cavernous hemangioma and in nonneoplastic soft-tissue lesions such as Morton's neuroma, ganglion cyst, and plantar fasciitis.^{2,3}

Statistics as to sex incidence vary, but most report a higher incidence in women. Subcutaneous ganglions are most common in the regions of the dorsum of the hand, palmar aspect of the wrist, palmar aspect of the fingers and dorsum of the foot. Recently intra-osseous ganglion, intraneural and intraligamentous ganglions have been described.^{4,5,6}

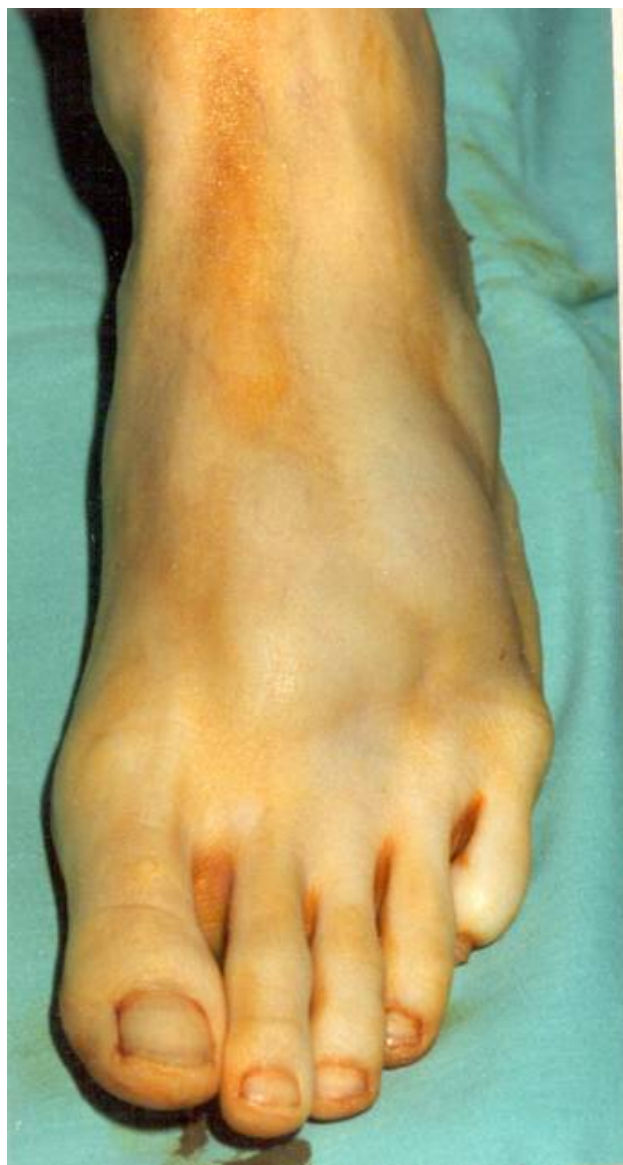

Figure 2 Massive left foot ganglion cyst to the dorsum of the foot.

Ganglion may recur locally, but after local excision, the recurrence rate is less than 10% after complete removal of the sac.² Ogose⁷ successfully treated a patient with large painful ganglion by OK-432 (lyophilized incubation mixture of group A *Streptococcus pyogenes*). Malignant changes in a ganglion are exceedingly rare.

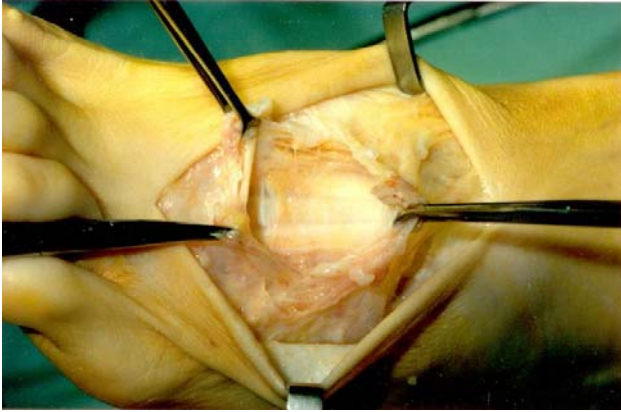


Figure 3 Removal of large dorsal foot ganglion cyst. No recurrence was reported after 2 years.

There are a wide variety of different lesions which present as lumps of the foot. There have been very few studies which look at the presenting characteristics or the differential diagnosis of such lesions. A differential diagnosis of lipomas, myxoid variant of monophasic fibrous synovial sarcoma, bursitis, fibroma should be considered.⁸ They suggested that there is a low diagnostic accuracy for foot lumps and, therefore, surgical excision and histological diagnosis should be sought if there is any uncertainty. Magnetic resonance imaging is the modality of choice in the assessment of soft tissue tumors. In the present case, MRI was not performed as clinically diagnosis was clear. The author generally relies on MRI for the diagnosis of all soft tissue lesions. In general, MRI does not provide histologic specificity, but considering some MR features may often help in correctly distinguishing benign from malignant lesions. In addition, characteristic features of the most common benign tumors (i.e., fibromatosis, ganglion cyst, Morton's neuroma) often suggest a specific diagnosis.⁹

To our best knowledge, this is one of the largest ganglions involving the dorsum of foot reported in adult literature.

References

1. [Llauger J, Palmer J, Monill JM, Franquet T, Bagué S, Rosón N](#). MR imaging of benign soft-tissue masses of the foot and ankle. *Radiographics*;18(6):1481-98,1998
2. [Kirby EJ, Shereff MJ, Lewis MM](#). Soft-tissue tumors and tumor-like lesions of the foot. An analysis of eighty-three cases. *J Bone Joint Surg Am*.71(4):621-6, 1989.
3. Pontius J, Good J, Maxian S. Ganglions of the foot and ankle, an retrospective analysis of 63 procedures. *J Am Podiatr Assoc* 89:163 168, 1999
4. [Murff R, Ashry HR](#). Intraosseous ganglia of the foot. *J Foot Ankle Surg*.;33(4):396-401,1994
5. [Battaglia TC, Freilich AM, Diduch DR](#). An intra-articular knee cyst in a 2-year-old associated with an aberrant anterior cruciate ligament. *Knee Surg Sports Traumatol Arthrosc*. 15(1):36-8,2007-12-
6. [Adn M, Hamlat A, Morandi X, Guegan Y](#). Intraneural ganglion cyst of the tibial nerve. *Acta Neurochir (Wien)*. 148(8):885-9; 2006
7. [Ogose A, Hotta T, Kawashima H, Endo N](#). A painful large ganglion cyst of the ankle treated by the injection of OK-432. *Mod Rheumatol*. 17(4):341-3,2007
8. [Macdonald DJ, Holt G, Vass K, Marsh A, Kumar CS](#). The differential diagnosis of foot lumps: 101 cases treated surgically in North Glasgow over 4 years. *Ann R Coll Surg Engl*. 89(3):272-5,2007
9. [Wetzel LH, Levine E](#). Soft-tissue tumors of the foot: value of MR imaging for specific diagnosis. *Foot Surg*. 31(3):272-5. 1992