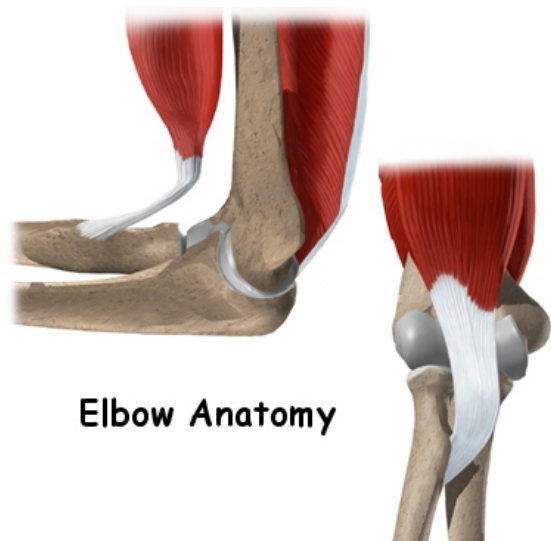




Vasu Pai MS, MCh, FRACS

Elbow Anatomy



Elbow Anatomy

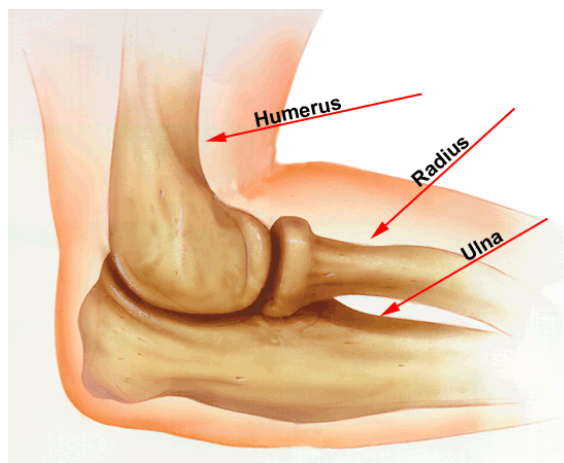


Figure 4. Normal anatomy of the elbow.

© 1996 American Academy of Orthopaedic Surgeons. Reprinted from the Journal of the American Academy of Orthopaedic Surgeons, Volume 4 (3), pp.117-128 with permission.

The elbow seems like a simple hinge.

Important Structures

The important structures of the elbow can be divided into several categories. These include
bones and joints
ligaments and tendons
muscles
nerves and blood vessels

Bones and Joints

The **bones of the elbow** are the humerus (the upper arm bone), the ulna (the larger bone of the forearm, on the opposite side of the thumb), and the radius (the smaller bone of the forearm on the same side as the thumb).

Ligaments and Tendons

A joint capsule is a watertight sac that surrounds a joint and contains lubricating fluid called synovial fluid.

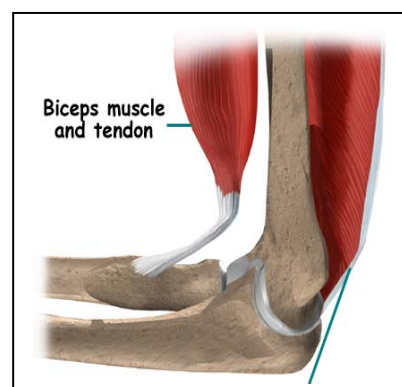
In the elbow, two of the most important ligaments are the **medial collateral ligament** and the **lateral collateral ligament**. The medial collateral is on the inside edge of the elbow, and the lateral collateral is on the outside edge.

There is also an important ligament called the **annular ligament** that wraps around the radial head and holds it tight against the ulna.

Muscles

The **triceps tendon** connects the large triceps muscle on the back of the arm with the ulna.

It allows the elbow to straighten with force, such as when you perform a push-up.



Nerves

All of the nerves that travel down the arm **pass across the elbow**. Three main nerves begin together at the shoulder: the radial nerve, the ulnar nerve, and the median nerve.

Blood Vessels

Traveling along with the nerves are the large vessels that supply the arm with blood . The largest artery is the **brachial artery** that travels across the front crease of the elbow.